

EXTRAPELVIC ENDOMETRIOSIS: IS IT AN IDIOPATHIC OR IATROGENIC DISEASE?

Hale Goksever Celik¹, Tolga Karaca², Cihan Kaya³, Mehmet Uhri⁴, Pinar Yalcin Bahat¹, Engin Oral⁵

¹ Department of Obstetrics and Gynecology, Saglik Bilimleri University Istanbul Kanuni Sultan Suleyman Training and Research Hospital, Istanbul, Turkey

² Department of Obstetrics and Gynecology, Saglik Bilimleri University Istanbul Bagcilar Training and Research Hospital, Istanbul, Turkey

³ Department of Obstetrics and Gynecology, Saglik Bilimleri University Istanbul Bakirkoy Dr Sadi Konuk Training and Research Hospital, Istanbul, Turkey

⁴ Department of Pathology, Saglik Bilimleri University Istanbul Bakirkoy Dr Sadi Konuk Training and Research Hospital, Istanbul, Turkey

⁵ Department of Obstetrics and Gynecology, Istanbul University Carrahpasa Faculty of Medicine, Istanbul, Turkey

Introduction and Objectives

Endometriosis is characterized by the presence of endometrial cells anywhere outside the uterine cavity. The most common sites of endometriosis are located in the pelvic cavity. However, endometriosis has been encountered outside the pelvic cavity named as extrapelvic endometriosis in which the endometrial cells attach to any other locations of the body including abdominal wall, gastrointestinal tract, urinary system, thoracic cavity, brain and musculature (1). Our aim in this study was to investigate the patients with extrapelvic endometriosis in tertiary referral centers from Istanbul and to compare them with the patients presented in the literature.

Methods

This retrospective observational study was conducted on the patients with histopathological diagnosis of extrapelvic endometriosis. All subjects were analyzed through a comprehensive medical assessment including documentation of the detailed history, physical and gynecological examination based on the patients' medical records.

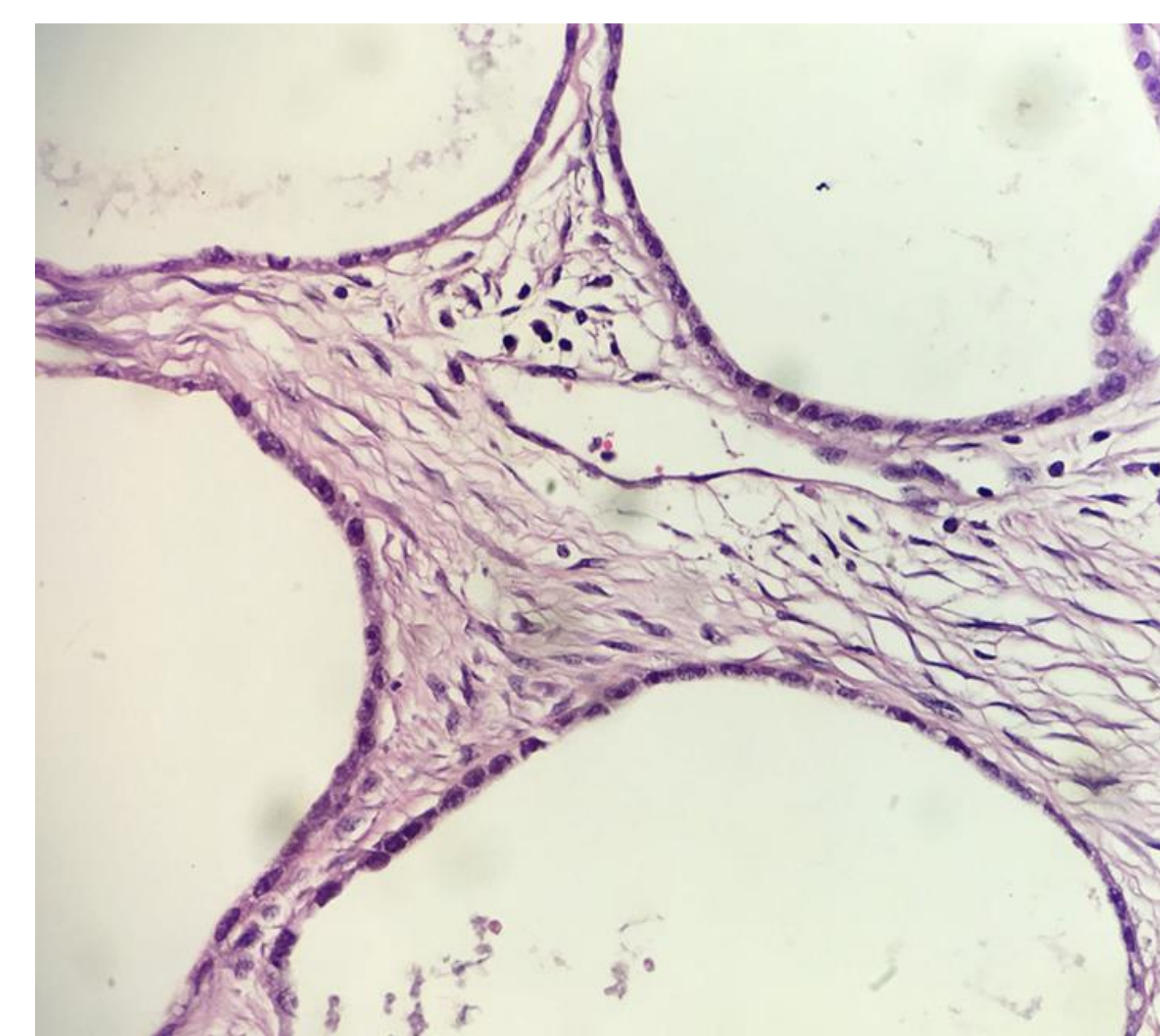
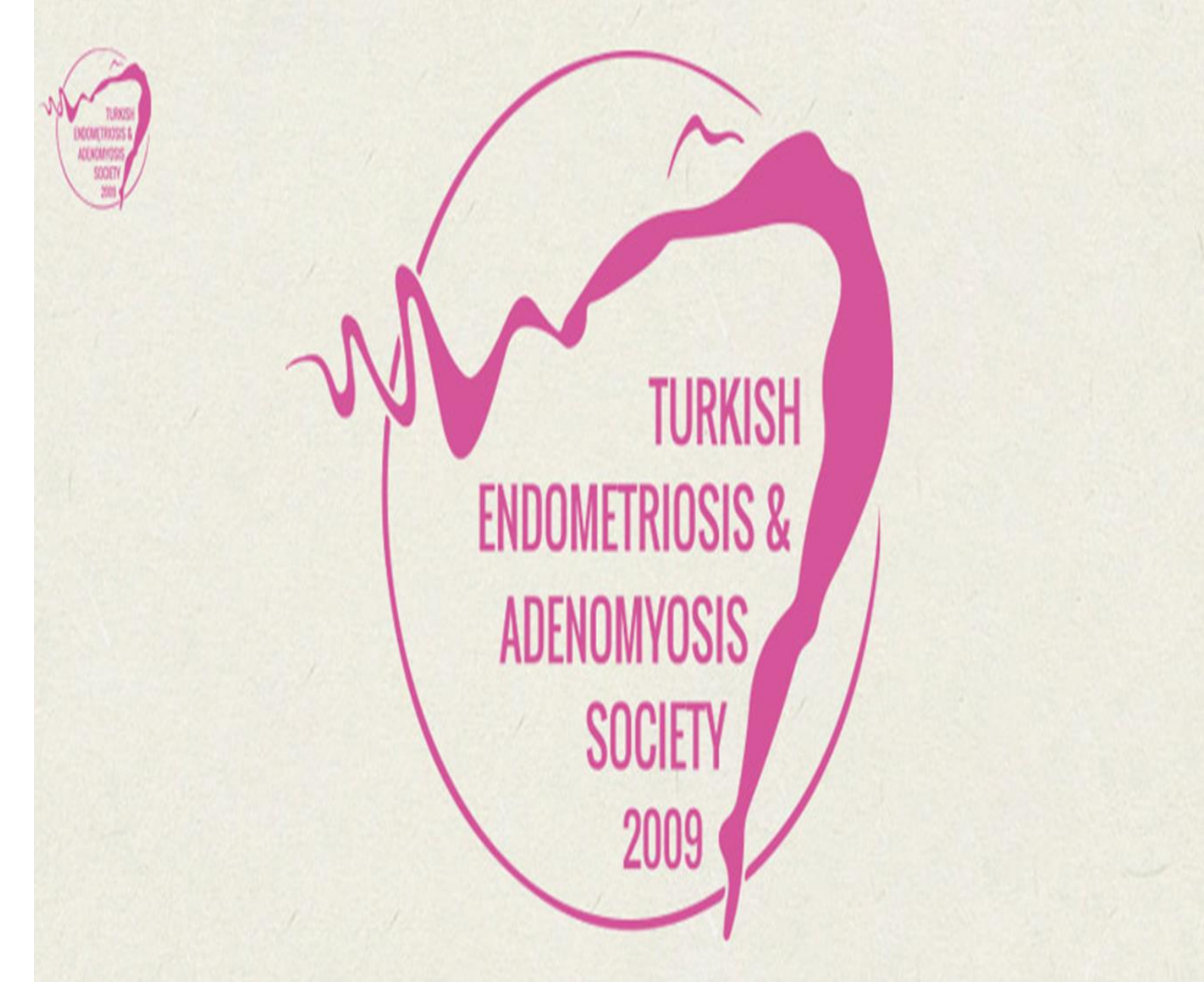Results and Conclusions

A total of 53 patients diagnosed with extrapelvic endometriosis were included in this study. The mean age and the mean BMI of the patients were 32.6 ± 6.5 years and 25.2 ± 3.5 kg/m², respectively. Most patients had at least one operation history whereas only 4 women had not underwent any surgery. The most common sites were presented in Table 1. The main symptom was the pain getting worse during menstruation and the presence of a mass in all patients. The main diagnostic tools in all patients were detailed history and physical examination, ultrasonography and then histopathological confirmation with surgical excision (Figures).

The most important responsibility of the clinicians in the extrapelvic endometriosis is to be careful in surgical procedures and to prevent its occurrence. Clinical suspicion has the most important place in correct diagnosis and management of extrapelvic endometriosis.

References

1- Davis AC, Goldberg JM. Extrapelvic Endometriosis. Semin Reprod Med. 2017; 35(1): 98-101.



Characteristics	number(%) or mean \pm standard deviation
Parity	
0	3 (5.7)
≥ 1	50 (94.3)
Size (cm)	3.1 \pm 1.1
Operation history	
Absent	4 (7.5)
Cesarean section	41 (77.4)
Cesarean section+laparotomy	8 (15.1)
Location	
Incision	30 (56.6)
Incision+Rectus abdominis muscle+Rectus sheath	10 (18.9)
Rectus abdominis muscle	4 (7.5)
Umbilicus	4 (7.5)
Inguinal region	2 (3.8)
Episiotomy	2 (3.8)
Vaginal posterior wall	1 (1.9)

