



Contents lists available at ScienceDirect

Reproductive Biology

journal homepage: www.elsevier.com/locate/repbio

Original article

Increased levels of proapoptotic markers in normal ovarian cortex surrounding small endometriotic cysts

Valentina Di Nisio^{a,1}, Gianna Rossi^{a,1}, Gianluca Di Luigi^b, Paola Palumbo^a, Angela D'Alfonso^a, Roberto Iorio^c, Sandra Ceconi^{a,*}

^a Department of Life, Health and Environmental Sciences, University of L'Aquila, L'Aquila, Italy

^b "Annunziata" Hospital Sulmona, L'Aquila, Italy

^c Department of Biotechnological and Applied Clinical Sciences, University of L'Aquila, L'Aquila, Italy

ARTICLE INFO

Keywords:

Endometriotic cyst

p53

Apoptosis

DNA repair

NFκB

ABSTRACT

Endometriosis can impair fertility by reducing ovarian reserve and the production of good-quality oocytes. The surgical removal of endometriotic lesions is generally recommended for women who wish to conceive. In this paper we studied whether ovarian cortex adjacent to excised small (diameter ≤ 4 cm) endometriotic cyst (here referred as Cortex Surrounding Endometriotic Cyst, CSEC) showed signs of tissue damages by evaluating the expression of proteins involved in DNA repair and apoptosis. To this end, phosphorylated H2A.X, Chk1 and 2, ATM and ATR, Bcl-2, Bid, phosphorylated and total p53, caspases (9, 8 and 3), XIAP, phosphorylated and total NFκB were analyzed by western blot. Results showed that caspase 8, XIAP, p53/p-p53 and NFκB were more abundantly expressed in all samples of CSEC group in comparison with ovarian cortex of controls. Conversely, the levels of the other proteins were comparable between the two groups. In conclusion, these results suggest that NFκB, caspase 8 and p53/p-p53 elevated expressions in samples of CSEC can be considered as an early sign of tissue injury, indicating that ovarian cortex is already sensitized to apoptosis and inflammation. Therefore, excision of EC should occur very early, to avoid further ovarian damages.

1. Introduction

Endometriosis is a pathology characterized by the presence of endometrial-like tissue outside the uterine cavity, that implants itself on pelvic organs, primarily ovaries and pelvic peritoneum, due to its enhanced survival, angiogenic, and proliferative potential [1]. The onset of this disease can be influenced by many factors, as abnormal steroid hormone response [2], altered epigenetic signature [3–5], and altered transcriptomic/proteomic profiles [5]. It elicits an inflammatory response, causing infertility and chronic pelvic pain in most cases [5].

Ovarian endometrioma, also called endometriotic cyst (EC), is considered one of the three major subtypes of endometriosis [6]. To date, the percentage of infertile women diagnosed with EC is about 17–44% [7,8]. The presence of EC affects *per se* morphological and functional characteristics of the ovarian cortex [9] and can determine either a significant reduction of ovarian reserve or the production of low-quality oocytes [8]. Independently of cyst size, the ovarian cortex surrounding EC is characterized by increased tissue fibrosis [10] and reduced follicular density [11], in comparison with the cortex adjacent

to non-endometriotic cysts. Indeed, the high concentration of toxic molecules detected within EC, as iron [12], leads to fibrosis of cells strictly in contact with the cyst wall [8].

Laparoscopic techniques utilized to reduce clinical symptoms and gonadotoxic effects are generally invasive [13,14], and can further impair residual ovarian functions [7,15–17]. Recently, ESHRE guidelines suggested that the cut off value of EC should be ≥ 3 cm [18], but several authors hypothesized that also endometriomas < 4 cm can severely damage ovarian tissue, thereby reducing ovarian reserve and responsiveness to gonadotropins [14].

To evaluate if ovarian cortex adjacent the wall of small EC having a diameter ≤ 4 cm showed signs of tissue insult, in this study we determined the contents of specific proteins involved in apoptosis and inflammation in samples of ovarian cortex either surrounding EC (Cortex Surrounding EC, CSEC) or surrounding other benign cysts, that were used as control.

* Corresponding author at: Department of Life, Health and Environmental Sciences, University of L'Aquila, Via Vetoio, Coppito 2, L'Aquila, Italy.

E-mail address: sandra.ceconi@univaq.it (S. Ceconi).

¹ Equal contribution.

<https://doi.org/10.1016/j.repbio.2019.08.002>

Received 8 March 2019; Received in revised form 2 August 2019; Accepted 3 August 2019

1642-431X/© 2019 Society for Biology of Reproduction & the Institute of Animal Reproduction and Food Research of Polish Academy of Sciences in Olsztyn.

Published by Elsevier B.V. All rights reserved.

2. Materials and methods

2.1. Chemicals

The following antibodies were purchased from Santa Cruz Biotechnology (Santa Cruz, CA, USA): mouse monoclonal Bcl-2 (sc-509), p53 (sc-65334); rabbit polyclonal phospho-NFκB p65 (Ser276, sc-101749), NFκB p65 (sc-372), Actin (sc-1616R). Mouse monoclonal Caspase-8 (cat. 9746); rabbit monoclonal Caspase-3 (cat. 9665); rabbit polyclonal Caspase-9 (cat. 9502), Bid (cat. 2002), XIAP (cat. 2042) and DNA Damage Antibody Sampler Kit (cat. 9947) were purchased from Cell Signaling Technology (Beverly, MA, USA). Specific secondary antibodies were purchased from Santa Cruz Biotechnology. Hybond C Extra was obtained from Amersham (Little Chalfont, UK); SuperSignal West Pico Chemiluminescent was purchased from Thermo Scientific (Rockford, IL, USA). All the other reagents were purchased from Sigma-Aldrich (St. Louis, MO, USA).

2.2. Ethical approval and informed consent

All procedures performed in studies involving human participants were in accordance with the ethical standards of the institutional and/or national research committee and with the 1964 Helsinki declaration and its later amendments or comparable ethical standards. This study has been reviewed and approved by the Internal Review Board of the University of L'Aquila (protocol number 09/2017, date of approval: 18 July 2017). Informed consent was obtained from all individual participants included in the study.

2.3. Sample collection

Fragments of ovarian cortical tissue were collected from women having small ovarian cysts (≤ 4 cm) and had undergone laparoscopic cystectomy from July 2017 to February 2018 at the Gynecological and Obstetrics Department of University Hospital of L'Aquila. All selected women fulfilled the following criteria: age 25–40 years, BMI 19–25, non-smokers, with no remarkable pathologies (diabetes, thyroid diseases and alcoholism). After histological examination (hematoxylin and eosin staining) performed by two independent pathologists, only biopsies without any contamination of endometriotic cells and inflammatory immune cells were included in the study. Following this selection, 25 women having small endometriotic cysts (EC), with a size ≤ 4 cm, were included in the study, while 10 women with benign non-endometriotic cysts (cystic teratoma, cystadenoma) were used as controls (Ctr). A small fragment of ovarian cortical tissue (5 x 5 x 2 mm), apparently healthy at macroscopic level, was excised at the time of cystectomy close to the wall of each cysts and was sliced into 3 pieces separately stored at -80°C until use.

2.4. Western blot analysis

For western blot analysis, samples of cortical tissue were crushed under liquid nitrogen and then homogenated for 30 min in lysis buffer (50 mM Tris, pH 7.4, 150 mM NaCl, 1 mM EDTA and 1% Igepal) containing protease (1 mM phenylmethylsulphonylfluoride, 1 $\mu\text{g}/\text{ml}$ leupeptin and 1 $\mu\text{g}/\text{ml}$ aprotinin) and phosphatase inhibitors (1 mM sodium fluoride, 10 mM sodium pyrophosphate and 1 mM sodium orthovanadate). Sonicated tissues were centrifuged at 14,000 x g for 20 min at 4°C . Supernatant protein concentration was measured using the Bio-Rad Protein Assay Dye Reagent Concentrate (#500-0006, Biorad, Hercules, CA, USA). Fifty μg of proteins were separated by electrophoresis and transferred to nitrocellulose membranes, that were incubated overnight at 4°C with the following primary antibodies: Actin, Bcl-2, p-NFκB, NFκB and p53 (1:200); p-p53, Caspase-3, Caspase-8, Caspase-9, Bid, XIAP, p-Chk1, p-Chk2, p-BRCA-1, p-Histone H2A.X, p-ATM and p-ATR (1:1000). Secondary antibodies (1:2000) were incubated for 1 h at room temperature. Peroxidase activity was detected using a SuperSignal West Pico Chemiluminescent substrate. The nitrocellulose membranes were examined using the Alliance LD2-77WL imaging system (Uvitec, Cambridge, UK). Densitometric quantification was performed with the public-domain software NIH Image V.1.62. For each antibody, lysates of specific cell lines were used as positive controls: Jurkat (Bcl-2, Bid, Caspases 3, 8 and 9), HeLa (XIAP, p-NFκB and NFκB), U251 (p-p53 and p53), COS treated with UV (p-Chk1, p-Chk2 and p-BRCA-1), 293 (p-Histone H2A.X and p-ATM), Raw264.7 (p-ATR).

2.5. Statistical analysis

All experiments were performed at least 3 times. Data obtained from CSEC and from control samples were normalized with the housekeeping protein (β -actin), pooled and expressed as mean \pm SEM. Comparisons between the 2 study groups (CSEC vs Ctr) were performed using Student's t-test. Results were considered statistically significant when $p < 0.05$. All statistical analysis was performed using the statistical package SigmaPlot (v. 11.0).

3. Results

3.1. DNA repair proteins and p53

In order to evaluate if the presence of small EC could injury the normal ovarian cortex surrounding the cyst wall despite the normal morphological appearance (Fig. 1), the contents of phosphorylated proteins specifically involved in DNA repair, as p-ATM/p-ATR, p-H2A.X, p-Chk1 and 2, p-BRCA-1 and p-p53/p53 were analyzed in ovarian cortex surrounding EC (CSEC) and surrounding other benign cysts (control, Ctr) samples. While the proteins repairing DNA were

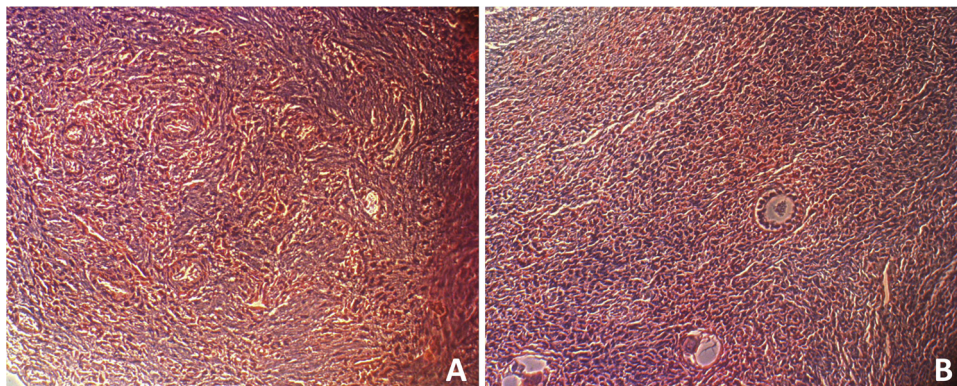


Fig. 1. Representative hematoxylin and eosin staining of histological sections of the cortex adjacent to benign non-endometriotic cysts (Ctr; A) and endometriotic cysts (CSEC; B). Original magnification 200 \times .

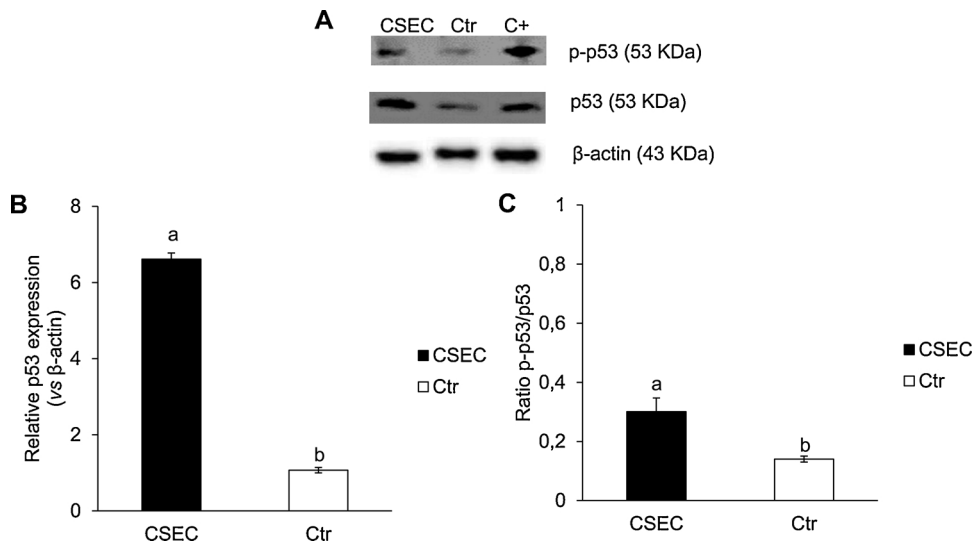


Fig. 2. Total and phosphorylated p53 expression in ovarian cortex surrounding endometriotic cysts (CSEC) or other benign cysts (control, Ctr). A. Representative images of p53 and p-p53 western blotting. B–C. Total p53 relative expression and p-p53/p53 ratio in CSEC and Ctr samples. Data are normalized vs β -actin, used as loading control. Bar graph data represent the mean \pm SEM of 3 independent determinations. Different letters: $p < 0.05$.

expressed at very low level in all the samples (Supplementary Fig. 1), significant overexpression of total and phosphorylated p53 was recognized in CSEC compared to Ctr (Fig. 2A-C; $p < 0.05$).

3.2. Apoptotic proteins

Detection of active caspase fragments showed that caspase 8 was significantly overexpressed in CSEC in comparison with Ctr (Fig. 3; $p < 0.05$), while caspases 9 and 3 levels were very low in both groups (Fig. 3). Similarly, no difference was recorded in Bcl-2 and t-Bid expression, which was faint/undetectable in all samples (Supplementary

Fig. 1; $p > 0.05$). Conversely, a three-fold increase of XIAP content was recorded in CSEC samples (Fig. 4; $p < 0.05$).

3.3. NF κ B and p-NF κ B

Since caspase 8 has an important function in modulating inflammation [19], levels of total and phosphorylated p65 subunit of the proinflammatory protein NF κ B were determined. Results shown in Fig. 5A-B evidenced an increased level of total NF κ B only in CSEC group ($p < 0.05$), while the phosphorylation status was comparable between the 2 experimental groups (Fig. 5C; $p > 0.05$).

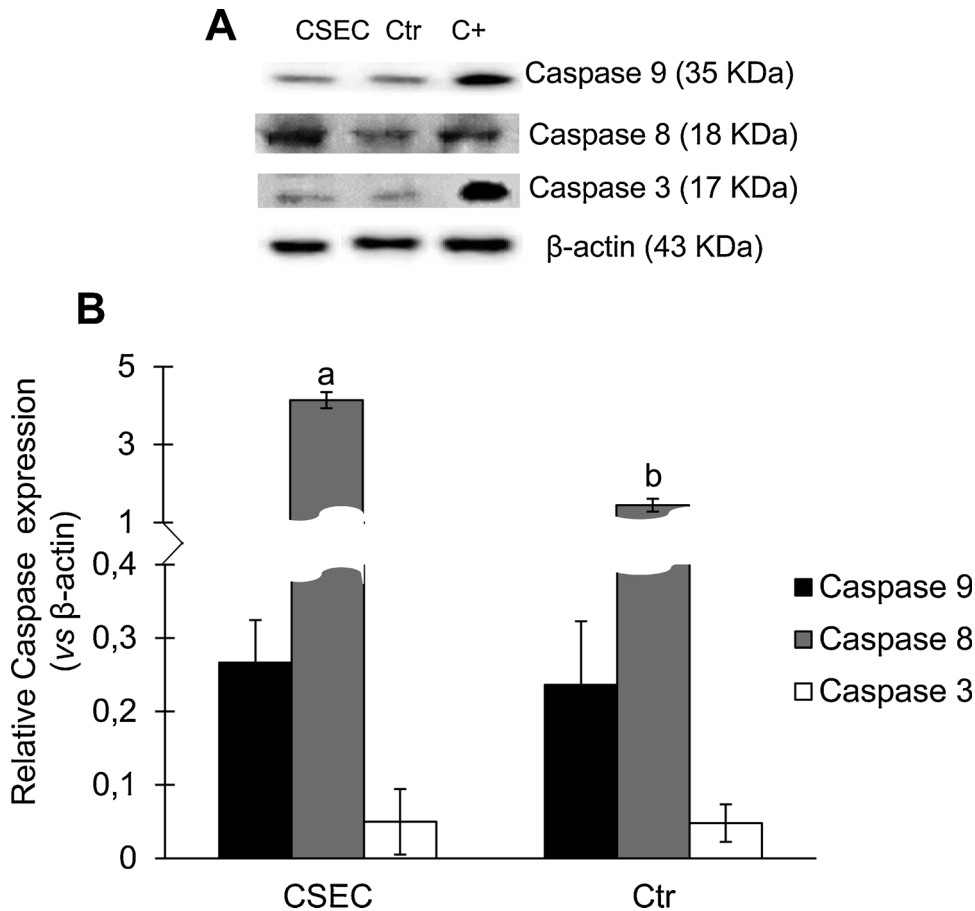


Fig. 3. Caspase 9, 8 and 3 expression in ovarian cortex surrounding endometriotic cysts (CSEC) or other benign cysts (control, Ctr). A. Representative images of active cleaved fragments of Caspase 9, 8 and 3 western blotting. B–C. Caspases relative expression in CSEC and Ctr samples. Data are normalized vs β -actin, used as loading control. Bar graph data represent the mean \pm SEM of 3 independent determinations. Different letters: $p < 0.05$.

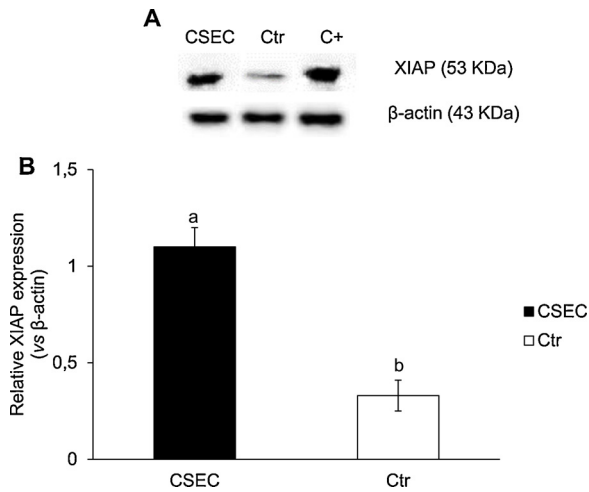


Fig. 4. XIAP expression in ovarian cortex surrounding endometriotic cysts (CSEC) or other benign cysts (control, Ctr). A. Representative images of XIAP western blotting. B–C. XIAP relative expression in CSEC and Ctr samples. Data are normalized vs β -actin, used as loading control. Bar graph data represent the mean \pm SEM of 3 independent determinations. Different letters: $p < 0.05$.

4. Discussion

In this study we analyzed the expression level of proteins involved in DNA repair and apoptotic pathways, finding that caspase 8 and total/phosphorylated p53 contents increased significantly in cortical tissue surrounding endometriotic cysts (CSEC) but not in that surrounding other benign cysts (control, Ctr).

EC are usually exposed to a high level of the inflammatory cytokine tumor necrosis factor α (TNF α) [20] and great oxidative stress [21]. In fact, the high content of free iron and ROS in cyst fluid [22] increases oxidative stress and, in the worst cases, the risk of having iron-dependent carcinogenesis. The tumor suppressor p53 plays a dual role in the management of oxidative stress response, acting as antioxidant or prooxidative factor, depending on the degree of oxidative stress [23]. The antioxidant functions of p53 are in keeping with enhanced cell survival through removal of oxidative stress and repair of DNA damages [23,24]. In the CSEC, the increment of p-p53/p53 contents indicates that any alteration of oxidative balance occurring in the apparently healthy cortical tissue is efficiently covered, as indicated by the under-expression of DNA damage-induced kinases. In fact, we found low/undetectable levels of active ATM/ATR, H2A.X, Chk1 and 2, BRCA-1,

all proteins actively involved in the repair of structural damages to DNA, as double-strand break and disruption of chromatin structure [25]. Furthermore, literature data on EC demonstrated that a rise in p53 total content, concomitantly with altered Bcl-2 expression, is considered causal or consequence of malignant transformation [26–29]. The low Bcl-2 content found in our samples confirms that no anomalous survival signals have been activated, yet. These results are in agreement with those by Nezhat and collaborators [26], who found that Bcl-2 staining was very low in benign EC but altered in benign-appearing areas of malignant EC.

The involvement of p53 in the regulation of both extrinsic and intrinsic apoptotic pathways [30] prompted us to assess caspases, the major effectors of apoptosis. From our results, it was evident that caspase 8, but not caspases 9, was overexpressed in CSEC but not in the cortex around other benign cysts. However, the finding that the high expression level of caspase 8 was not concomitant with those of caspase 3 and Bid/t-Bid excluded the completion of apoptotic pathway. The lack of interaction between caspase 8 and caspase 3 can be explained by the activity of the X-linked inhibitor of apoptosis proteins (XIAP), which inhibits caspases 3 and 9 activation sites [31].

In many cellular models, XIAP and caspase 8 stimulates NF κ B nuclear translocation via ubiquitination of its repressors, IKK β and I κ B α [31–33]. In the nucleus, NF κ B drives the transcription of several proinflammatory genes [34,35] and of p53 [36]. The phosphorylation of nuclear NF- κ B p65 at Ser276 can be considered either as a potential marker of premalignant to malignant transition, or as a response to inflammatory factors, such as TNF- α [37]. Therefore, we investigated whether this mediator could be activated also in our samples. Although in our study we do not investigate if the accumulation of NF κ B in CSEC samples could correspond to its full activity, the low Ser-276 phosphorylation status confirms the absence of a sustained stressful response [38]. This is confirmed also by the lack of active ATM, which can trigger via TNF α the phosphorylation of p65 at Ser276 [39].

Altogether, our results evidence that the maintenance of an altered cellular microenvironment could induce, with time, extensive cellular damage and the malignant transformation of normal tissue around EC cannot be excluded, as sustained by several literature data [40–42]. Although the tissues here analyzed do not show evident morphological cell damages nor severe molecular alterations, in our opinion EC should be removed when their diameter is very small and when anomalous cell survival signaling is not yet completely activated. Our conclusions are in keeping with that of Sanchez and colleagues [8], who found that EC damage the ovary independently from their diameters, and in accordance with ESHRE guidelines [43], which suggest the early removal of EC to better preserve the residual ovarian tissue quality.

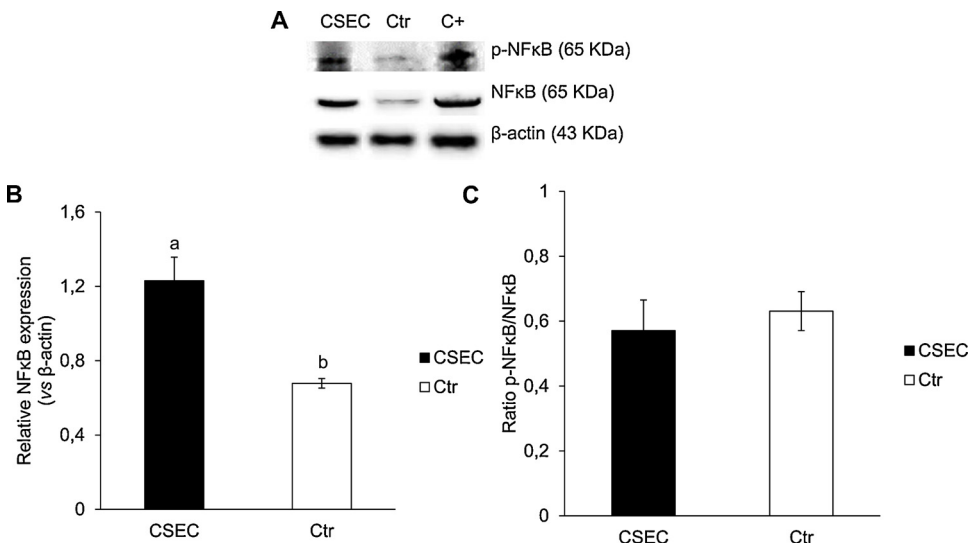


Fig. 5. Total and phosphorylated NF κ B expression in ovarian cortex surrounding endometriotic cysts (CSEC) or other benign cysts (control, Ctr). A. Representative images of NF κ B and p-NF κ B western blotting. B–C. Total NF κ B relative expression and p-NF κ B/NF κ B ratio in CSEC and Ctr samples. Data are normalized vs β -actin, used as loading control. Bar graph data represent the mean \pm SEM of 3 independent determinations. Different letters: $p < 0.05$.

Funding sources

This research was supported by Ministero dell'Università e della Ricerca, Italy (RIA 2016-17) to S.C.

Declaration of Competing Interest

None.

Acknowledgements

The authors would like to dedicate this paper in memory of Professor Gaspare Carta. They express their gratitude to Professor Maria Grazia Cifone and Professor Benedetta Cinque for their helpful suggestions and for critically reading the manuscript, and to Dr. Fatima Carla Bassi for the English editing of the manuscript.

Appendix A. Supplementary data

Supplementary material related to this article can be found, in the online version, at doi:<https://doi.org/10.1016/j.repbio.2019.08.002>.

References

- Giudice LC. Clinical practice. Endometriosis. *N Engl J Med* 2010;362(25):2389–98. <https://doi.org/10.1056/NEJMcp1000274>.
- Kitawaki J, Kado N, Ishihara H, Koshiba H, Kitaoka Y, Honjo H. Endometriosis: the pathophysiology as an estrogen-dependent disease. *J Steroid Biochem Mol Biol* 2002;83(1-5):149–55. [https://doi.org/10.1016/S0960-0760\(02\)00260-1](https://doi.org/10.1016/S0960-0760(02)00260-1).
- May KE, Villar J, Kirtley S, Kennedy SH, Becker CM. Endometrial alterations in endometriosis: a systematic review of putative biomarkers. *Hum Reprod Update* 2011;17(5):637–53. <https://doi.org/10.1093/humupd/dmr013>.
- Afshar Y, Hastings J, Roqueiro D, Jeong JW, Giudice LC, Fazleabas AT. Changes in eutopic endometrial gene expression during the progression of experimental endometriosis in the baboon, *Papio anubis*. *Biol Reprod* 2013;88(2):44. <https://doi.org/10.1095/biolreprod.112.104497>.
- Houshdaran S, Nezhat CR, Vo KC, Zelenko Z, Irwin JC, Giudice LC. Aberrant Endometrial DNA Methylation and Associated Gene Expression in Women with Endometriosis. *Biol Reprod* 2016;95(5):93. <https://doi.org/10.1095/biolreprod.116.140434>.
- Nisolle M, Donnez J. Peritoneal endometriosis, ovarian endometriosis, and adenomyotic nodules of the rectovaginal septum are three different entities. *Fertil Steril* 1997;68(4):585–96. [https://doi.org/10.1016/S0015-0282\(97\)00191-X](https://doi.org/10.1016/S0015-0282(97)00191-X).
- García-Velasco JA, Somigliana E. Management of endometriomas in women requiring IVF: to touch or not to touch. *Hum Reprod* 2009;24(3):496–501. <https://doi.org/10.1093/humrep/den398>.
- Sanchez AM, Viganò P, Somigliana E, Panina-Bordignon P, Vercellini P, Candiani M. The distinguishing cellular and molecular features of the endometriotic ovarian cyst: from pathophysiology to the potential endometrioma-mediated damage to the ovary. *Hum Reprod Update* 2014;20(2):217–30. <https://doi.org/10.1093/humupd/dmt053>.
- Muzii L, Bianchi A, Crocè C, Mancini N, Panici PB. Laparoscopic excision of ovarian cysts: is the stripping technique a tissue-sparing procedure? *Fertil Steril* 2002;77(3):609–14. [https://doi.org/10.1016/S0015-0282\(01\)03203-4](https://doi.org/10.1016/S0015-0282(01)03203-4).
- Schubert B, Canis M, Darcha C, Artonne C, Pouly JL, Déchelotte P, et al. Human ovarian tissue from cortex surrounding benign cysts: a model to study ovarian tissue cryopreservation. *Hum Reprod* 2005;20(7):1786–92. <https://doi.org/10.1093/humrep/dei002>.
- Kitajima M, Defrère S, Dolmans MM, Colette S, Squifflet J, et al. Donnez J. Endometriomas as a possible cause of reduced ovarian reserve in women with endometriosis. *Fertil Steril* 2011;96(3):685–91. <https://doi.org/10.1016/j.fertnstert.2011.06.064>.
- Yamaguchi K, Mandai M, Toyokuni S, Hamanishi J, Higuchi T, Takakura K, et al. Contents of endometriotic cysts, especially the high concentration of free iron, are a possible cause of carcinogenesis in the cyst through the iron-induced persistent oxidative stress. *Clin Cancer Res* 2008;14(1):32–40. <https://doi.org/10.1158/1078-0432.CCR-07-1614>.
- Hart R, Hickey M, Maouris P, Buckett W, Garry R. Excisional surgery versus ablative surgery for ovarian endometrioma: a Cochrane Review. *Hum Reprod* 2005;20(11):3000–7. <https://doi.org/10.1093/humrep/dei207>.
- Tang Y, Chen SL, Chen X, He YX, Ye DS, Guo W, et al. Ovarian damage after laparoscopic endometrioma excision might be related to the size of cyst. *Fertil Steril* 2013;100(2):464–9. <https://doi.org/10.1016/j.fertnstert.2013.03.033>.
- Benaglia L, Somigliana E, Vighi V, Ragni G, Vercellini P, Fedele L. Rate of severe ovarian damage following surgery for endometriomas. *Hum Reprod* 2010;25(3):678–82. <https://doi.org/10.1093/humrep/dep464>.
- Somigliana E, Benaglia L, Vercellini P, Paffoni A, Ragni G, Fedele L. Recurrent endometrioma and ovarian reserve: biological connection or surgical paradox? *Am J Obstet Gynecol* 2011;204(6):529. <https://doi.org/10.1016/j.ajog.2011.01.053>.
- Keyhan S, Hughes C, Price T, Muasher S. An Update on Surgical versus Expectant Management of Ovarian Endometriomas in Infertile Women. *Biomed Res Int* 2015;2015:204792. <https://doi.org/10.1155/2015/204792>.
- Dunselman GA, Vermeulen N, Becker C, Calhaz-Jorge C, D'Hooghe T, et al. Nelen W; ESHRE guideline: management of women with endometriosis. *Hum Reprod* 2014;29(3):400–12. <https://doi.org/10.1093/humrep/det457>.
- Gurung P, Kanneganti TD. Novel roles for caspase-8 in IL-1beta and inflammasome regulation. *Am J Pathol* 2015;185(1):17–25. <https://doi.org/10.1016/j.ajpath.2014.08.025>.
- Kocbek V, Grandi G, Blank F, Wotzkow C, Bersinger NA, Mueller MD, et al. TNF α -induced IKK β complex activation influences epithelial, but not stromal cell survival in endometriosis. *Mol Hum Reprod* 2016;22(11):768–77. <https://doi.org/10.1093/molehr/gaw054>.
- Scutiero G, Iannone P, Bernardi G, Bonaccorsi G, Spadaro S, Volta CA, et al. Oxidative stress and endometriosis: a systematic review of the literature. *Oxid Med Cell Longev* 2017;2017:7265238. <https://doi.org/10.1155/2017/7265238>.
- Yamaguchi K, Mandai M, Toyokuni S, Hamanishi J, Higuchi T, Takakura K, et al. Contents of endometriotic cysts, especially the high concentration of free iron, are a possible cause of carcinogenesis in the cysts through the iron-induced persistent oxidative stress. *Clin Cancer Res* 2008;14(1):32–40. <https://doi.org/10.1158/1078-0432.CCR-07-1614>.
- Liu D, Xu Y. p53, Oxidative stress, and aging. *Antioxid Redox Signal* 2011;15(6):1669–78. <https://doi.org/10.1089/ars.2010.3644>.
- Horn HF, Vousden KH. Coping with stress: multiple ways to activate p53. *Oncogene* 2007;26(9):1306–16. <https://doi.org/10.1038/sj.onc.1210263>.
- Hakem R. DNA-damage repair; the good, the bad, and the ugly. *EMBO J* 2008;27(4):589–605. <https://doi.org/10.1038/emboj.2008.15>.
- Nezhat F, Cohen C, Rahaman J, Gretz H, Cole P, Kalir T. Comparative immunohistochemical studies of bcl-2 and p53 proteins in benign and malignant ovarian endometriotic cysts. *Cancer* 2002;94(11):2935–40. <https://doi.org/10.1002/cncr.10566>.
- Han AC, Hovenden S, Rosenblum NG, Salazar H. Adenocarcinoma arising in extragonadal endometriosis: an immunohistochemical study. *Cancer* 1998;83(6):1163–9.
- Marone M, Scambia G, Mozzetti S, Ferrandina G, Iacovella S, et al. Bcl-2, bax, bcl-XL, and bcl-XS expression in normal and neoplastic ovarian tissues. *Clin Cancer Res* 1998;4(2):517–24.
- Geisler JP, Geisler HE, Miller GA, Wiemann MC, Zhou Z, Crabtree W. p53 and bcl-2 in epithelial ovarian carcinoma: their value as prognostic indicators at a median follow-up of 60 months. *Gynecol Oncol* 2000;77(2):278–82. <https://doi.org/10.1006/gyno.2000.5780>.
- Haupt S, Berger M, Goldberg Z, Haupt Y. Apoptosis - the p53 network. *J Cell Sci* 2003;116(Pt 20):4077–85. <https://doi.org/10.1242/jcs.00739>.
- de Almagro MC, Vucic D. The inhibitor of apoptosis (IAP) proteins are critical regulators of signaling pathways and targets for anti-cancer therapy. *Exp Oncol* 2012;34(3):200–11.
- Su H, Bidère N, Zheng L, Cubre A, Sakai K, Dale J, et al. Requirement for caspase-8 in NF- κ B activation by antigen receptor. *Science* 2005;307(5714):1465–8. <https://doi.org/10.1126/science.1104765>.
- Henry CM, Martin SJ. Caspase-8 acts in a non-enzymatic role as a scaffold for assembly of a pro-inflammatory "FADDosome" complex upon trail stimulation. *Mol Cell* 2017;65(4):715–29. <https://doi.org/10.1016/j.molcel.2017.01.022>.
- Lawrence T. The nuclear factor NF- κ B pathway in inflammation. *Cold Spring Harb Perspect Biol* 2009;1(6):a001651. <https://doi.org/10.1101/cshperspect.a001651>.
- Oberst A, Green DR. It cuts both ways: reconciling the dual roles of caspase 8 in cell death and survival. *Nat Rev Mol Cell Biol* 2011;12(11):757–63. <https://doi.org/10.1038/nrm3214>.
- Zhang LH, Youn HD, Liu JO. Inhibition of cell cycle progression by the novel cyclophilin ligand sanglifehrin A is mediated through the NF- κ B-dependent activation of p53. *J Biol Chem* 2001;276(47):43534–40. <https://doi.org/10.1074/jbc.M104257200>.
- Arun P, Brown MS, Ehsanian R, Chen Z, Van Waas C. Nuclear NF- κ B p65 phosphorylation at serine 276 by protein kinase A contributes to the malignant phenotype of head and neck cancer. *Clin Cancer Res* 2009;15(19):5974–84. <https://doi.org/10.1158/1078-0432.CCR-09-1352>.
- Hayden MS, Ghosh S. NF- κ B, the first quarter-century: remarkable progress and outstanding questions. *Genes Dev* 2012;26(3):203–34. <https://doi.org/10.1101/gad.183434.111>.
- Fang L, Choudhary S, Zhao Y, Edeh CB, Yang C, Boldogh I, et al. ATM regulates NF- κ B-dependent immediate-early genes via RelA Ser 276 phosphorylation coupled to CDK9 promoter recruitment. *Nucleic Acids Res* 2014;42(13):8416–32. <https://doi.org/10.1093/nar/gku529>.
- Haidarali E, Vahedi A, Mohajeri Sh, Mostafaei E, Azimpouran M, et al. Evaluation of the Pathogenesis of Tumor Development from Endometriosis by Estrogen Receptor, P53 and Bcl-2 Immunohistochemical Staining. *Asian Pac J Cancer Prev* 2016;17(12):5247–50. <https://doi.org/10.22034/APJCP.2016.17.12.5247>.
- Lee WL, Chang WH, Wang KC, Guo CY, Chou YJ, Huang N, et al. The risk of epithelial ovarian cancer of women with endometriosis may be varied greatly if diagnostic criteria are different: a nationwide population-based cohort study. *Medicine (Baltimore)* 2015;94(39):e1633. <https://doi.org/10.1097/MD.0000000000001633>.
- Torgn PL. Clinical implication for endometriosis associated with ovarian cancer. *Gynecol Minim Invasive Ther* 2017;6(4):152–6. <https://doi.org/10.1016/j.gmit.2017.08.003>.
- Saridogan E, Becker CM, Feki A, Grimbizis GF, Hummelshoj L, Keckstein J, et al. Recommendations for the surgical treatment of endometriosis-part 1: ovarian endometrioma. *Gynecol Surg* 2017;14(1):27. <https://doi.org/10.1186/s10397-017-1029-x>.