

Painful Love: Superficial Dyspareunia and Three Dimensional Transperineal Ultrasound Evaluation of Pelvic Floor Muscle in Women with Endometriosis

Mohamed Mabrouk, Simona Del Forno, Alessandra Spezzano, Diego Raimondo, Alessandro Arena, Margherita Zanello, Deborah Leonardi, Roberto Paradisi & Renato Seracchioli

To cite this article: Mohamed Mabrouk, Simona Del Forno, Alessandra Spezzano, Diego Raimondo, Alessandro Arena, Margherita Zanello, Deborah Leonardi, Roberto Paradisi & Renato Seracchioli (2019): Painful Love: Superficial Dyspareunia and Three Dimensional Transperineal Ultrasound Evaluation of Pelvic Floor Muscle in Women with Endometriosis, Journal of Sex & Marital Therapy, DOI: [10.1080/0092623X.2019.1676852](https://doi.org/10.1080/0092623X.2019.1676852)

To link to this article: <https://doi.org/10.1080/0092623X.2019.1676852>



Published online: 15 Oct 2019.



Submit your article to this journal [↗](#)



Article views: 55



View related articles [↗](#)



View Crossmark data [↗](#)



Painful Love: Superficial Dyspareunia and Three Dimensional Transperineal Ultrasound Evaluation of Pelvic Floor Muscle in Women with Endometriosis

Mohamed Mabrouk^{a,b}, Simona Del Forno^a, Alessandra Spezzano^a, Diego Raimondo^a, Alessandro Arena^a, Margherita Zanello^a, Deborah Leonardi^a, Roberto Paradisi^a, and Renato Seracchioli^a

^aGynaecology and Human Reproduction Physiopathology, DIMEC, S. Orsola Hospital, University of Bologna, Bologna, Italy; ^bDepartment of Obstetrics and Gynaecology, Faculty of Medicine, University of Alexandria, Alexandria, Egypt

ABSTRACT

We conducted an observational study between March 2015 and March 2018 in our academic center. Symptomatic, sexually active women with clinical and sonographic diagnosis of deep infiltrating endometriosis (DIE) or isolated ovarian endometriosis were enrolled. Women were asked to rank endometriosis-related symptoms, especially superficial and deep dyspareunia. Moreover, 3D transperineal ultrasound was performed to assess the levator hiatus area (LHA) evaluating pelvic floor muscle (PFM) morphometry. Women with endometriosis seem to have a high prevalence of superficial dyspareunia and three-dimensional transperineal ultrasound seems to be a viable technique to assess PFM morphometry in these women.

Introduction

Endometriosis is a chronic inflammatory disease, defined as the abnormal presence of endometrial tissue outside the uterine cavity (Cornillie, Oosterlynck, Lauweryns, & Koninckx, 1990). There are different types of endometriosis: superficial peritoneal implants, ovarian cysts called endometriomas, or deep infiltrating endometriosis (DIE) when the endometrial tissue penetrates the pelvic structures below the surface of the peritoneum (Seracchioli et al., 2007). DIE, which can cause adhesions and anatomy distortions, is the most severe form of the disease. Endometriosis may cause pain symptoms, which negatively affect health and quality of life of women during reproductive age (Marinho et al., 2017). Dyspareunia, defined as painful sexual intercourse, is one of the most common symptoms associated with DIE. Dyspareunia can be classified as: *superficial dyspareunia*, defined as complaint of pain or discomfort on vaginal entry or at the vaginal introitus, or *deep dyspareunia*, defined as complaint of pain or discomfort on deeper penetration (mid or upper vagina). (Rogers et al., 2018) Several studies evaluated sexual activity in women with endometriosis, demonstrating that sexual dysfunction is closely related to pain intensity during or after intercourse, with less sexual intercourse per month, with a greater feeling of guilt towards the partner and with a lower sense of femininity (Di Donato et al., 2014; Fritzer et al., 2013). The connection between endometriosis, particularly DIE, and deep dyspareunia has already been investigated (Shum, Bedaiwy, Yong, 2018). The presence of endometriotic

lesions infiltrating the posterior vaginal fornix, the pouch of Douglas, the uterosacral ligaments, and the rectum may cause deep pain to sexual intercourse due to the mechanical pressure on the lesions or due to the traction of the rigid endometriotic tissue. Women with endometriosis may experience sexual impairments, with negative consequences on their psychological and physical health and quality of life, especially considering the chronic nature of the disease and its association with infertility (Barbara et al., 2017; Montanari et al., 2013).

On the other hand, very little is known about endometriosis and superficial dyspareunia, as well as the role of the pelvic floor muscle (PFM) tone in women with DIE complaining dyspareunia (Shum et al., 2018; Yong, Sadownik, & Brotto, 2015).

The PFM tone can be evaluated by three-dimensional (3D) transperineal ultrasound, a valid, reliable and noninvasive technique, through the assessment of the levator hiatus area (LHA) (Hans Peter Dietz, 2017). In recent studies, we measured LHA in women with endometriosis and the results showed a smaller area in women with DIE compared to controls and to women with isolated ovarian endometriosis. (Mabrouk et al., 2018; Raimondo et al., 2017)

The aim of the present study was to investigate the presence of superficial dyspareunia in women with endometriosis and the correlation between superficial dyspareunia and PFM morphometry, assessed with transperineal 3D ultrasound.

Materials and methods

Subjects

An observational study was conducted between March 2015 and March 2018 in our referral center for endometriosis. One hundred and sixty nulliparous, sexually active women with clinical and sonographic diagnosis of DIE or ovarian endometriosis, scheduled for surgery, were enrolled in the study. Diagnosis of endometriosis was based on clinical and sonographic findings and, when necessary, on magnetic resonance imaging (MRI). Ultrasonographic diagnosis of endometriosis was made in all patients according to IDEA criteria. (Guerriero et al., 2016) Women had to report at least one sexual intercourse in the last four weeks. Data on medical history, age, body mass index, current or previous hormonal therapies and previous surgery were collected. Women with deep infiltrating lesions were included in the “DIE group”, while women with an isolated diagnosis of ovarian endometriosis were included in the “OVA group”. Exclusion criteria were: age less than 18 or more than 45 years, ongoing pregnancy, previous vaginal deliveries, previous surgery for deep endometriosis, women with simultaneous DIE and ovarian endometriosis, endometriotic vaginal nodules, postmenopausal status, active urinary or vaginal infection, history of other identifiable causes of pelvic pain or pelvic floor dysfunction (pelvic organ prolapse, pelvic inflammatory disease, interstitial cystitis, irritable bowel disease, active urinary or vaginal infection, diagnosis of genital malignancy, congenital or acquired pelvic floor abnormalities, sexual abuse). Patients gave written informed consent to participate to the study. The approval of the study protocol was obtained from our local Ethics Committee (196/2015/O/Sper).

Symptoms and dyspareunia

Women were asked to rank endometriosis related symptoms (dysmenorrhea, dysuria, dyschezia, chronic pelvic pain) using a 11-point numerical rating scale (NRS).

Female doctors asked women privately if they experienced pain during sexual intercourse (dyspareunia). Women who replied positively were then asked to specify if the pain was during vaginal penetration, occurring in/or around the vaginal entrance (*superficial dyspareunia*); or if deep pain was felt in the vagina and in the pelvis after deep vaginal penetration (*deep dyspareunia*). The severity of both superficial and deep dyspareunia was assessed with a NRS. Women who

assigned NRS score > 0 only to superficial or deep dyspareunia were classified as having respectively isolated superficial or deep dyspareunia, while if the NRS score was > 0 for both questions women were classified as having concomitant dyspareunia. If the NRS score was 0 for both symptoms, dyspareunia was assumed to be absent in those women.

Considering the absence of validated and specific questionnaires to investigate the frequency of superficial and deep dyspareunia, we adapted questions 17 and 18 from the Female Sexual Function Index (FSFI) questionnaire (Rosen et al., 2000), that we used in our daily practice in the validated Italian version (Filocamo et al., 2014). In particular, women were asked to answer the following questions, assigning the same FSFI score (score 1–4), as reported in the [Appendix Table A1](#):

- question A: ‘How often did you experience pain during vaginal penetration occurring in/around the vaginal entrance (*superficial dyspareunia*)?’
- question B: ‘How often did you experience deep pain felt in the vagina and in the pelvis following vaginal penetration (*deep dyspareunia*)?’

Ultrasound technique

Three-dimensional transperineal ultrasound was performed to evaluate PMF morphometry at rest by experienced sonographers, before gynaecological bimanual examination, transvaginal and transabdominal ultrasound (Youssef et al., 2016). All acquisitions were recorded with a Voluson E6 system (GE Healthcare, Zipf, Austria) using a convex volumetric transducer RAB 8-4-MHz, a high quality acquisition and an angle of 85° . The probe was positioned translabially on the midsagittal plane, with the woman in a modified lithotomic position, after emptying the bladder. The levator hiatus area (LHA) was delimited by the puborectalis muscle, the pubic symphysis and the inferior pubic ramus, as previously described (Morin, Bergeron, Khalifé, Mayrand, & Binik, 2014).

All data were later analyzed by two different experienced operators blinded to the clinical data using a dedicated software (4D View 14.4; GE Healthcare), demonstrating no significant differences between operators’ evaluations (intra-class correlation coefficients resulted higher than 0.80, indicating very high agreement between the two operators).

Statistical analysis

Continuous data were expressed in terms of mean \pm SD or median (range). Categorical variables were expressed as numbers and percentages and evaluated with the Chi-Square test. The Student t-test and Mann-Whitney U test were used to compare continuous parametric and non-parametric variables, respectively. A P-value of <0.05 was considered significant for all tests. We performed a power analysis based on data from a previous study on PFM morphometry (Mabrouk et al., 2018). In this study, LHA at rest had a mean of $11.9 \pm 2.45 \text{ cm}^2$. Assuming a true difference of 1.1 cm^2 in mean LHA (10%) between women with DIE and women with OVA, we estimated a sample size of 156 to be able to reject the null hypothesis that the population means of the two groups are equal with probability (power) 0.8. The type I error probability associated with testing this hypothesis was 0.05. Spearman correlation was used to evaluate the relationship between the frequency of superficial dyspareunia and LHA at rest in the entire study group. Statistical analysis was carried out using the Statistical Package for the Social Sciences (SPSS) software version 24.0 (IBM Corp., Armonk, NY, USA).

Table 1. Baseline characteristics, localizations of endometriotic lesions and symptoms in the two groups.

	OVA group (n = 79)	DIE group (n = 81)	P value
Age, y, mean \pm SD	34.8 \pm 8.4	36.5 \pm 6.9	.19
Body Mass Index, kg/m ² , mean \pm SD	21.6 \pm 5.0	22.7 \pm 3.6	.11
Localization of endometriotic lesions, n (%)			
Ovaries	79 (100%)	0	
Recto-vaginal septum	0	30 (36.1%)	
Rectum	0	49 (59.0%)	
Sigmoid colon	0	12 (14.5%)	
Ureters	0	16 (19.3%)	
Utero-sacral ligaments	0	23 (27.7%)	
Parametrium	0	7 (8.4 %)	
Pain symptoms, NRS (mean \pm SD)			
Dyschezia	1.5 \pm 2.2	4.6 \pm 3.4	<.001
Dysuria	1.3 \pm 2.3	2.2 \pm 1.8	<.001
Dysmenorrhea	3.1 \pm 3.1	5.6 \pm 3.0	<.001
Chronic pelvic pain	3.8 \pm 3.1	4.9 \pm 3.3	.026
Superficial Dyspareunia	3.3 \pm 3.3	4.4 \pm 3.2	.036
Deep Dyspareunia	3.9 \pm 3.8	5.8 \pm 4.0	.003

Age and BMI were compared with student t test. Symptoms were compared with Mann-Whitney test. NRS: Numeric Rating Scale.

Results

Of the one hundred and sixty women enrolled in the study, 81 entered in the DIE group and 79 in the OVA group. Baseline characteristics, pain symptoms and localizations of the disease are reported in [Table 1](#). Pre-operative transperineal ultrasound was successfully performed in all women. All women underwent complete laparoscopic excision of endometriotic lesions. Endometriosis diagnosis was confirmed by histological examination in all women.

Prevalence of dyspareunia

The overall prevalence of dyspareunia in the study group was 78.1% (125/160). In particular, women in the DIE group experienced dyspareunia more frequently (69/81, 85.2%) than women in the OVA group (56/79, 70.9%) ($P = .028$; χ^2 test). Superficial dyspareunia, which was present in 108 women in all the study group (108/160, 67.5%), was mainly concomitant with deep dyspareunia (90/108, 83.3%). The prevalence of exclusive superficial dyspareunia was 11.3% (18/160) in the entire study group. A significant higher prevalence of superficial dyspareunia (isolated or concomitant with deep dyspareunia) was detected in the DIE group compared to the OVA group (61/81, 75.3% in DIE group versus 47/79, 59.5% in OVA group; $P = .032$; χ^2 test). Regarding pain severity, the NRS scores of superficial and deep dyspareunia were significantly higher in the DIE group than in the OVA group ([Table 1](#)).

Frequency of both superficial dyspareunia and deep dyspareunia, assessed by question A and B, was more significantly higher in the DIE group compared with the OVA group (2.53 \pm 1.54 in the DIE group versus 3.15 \pm 1.60 in the OVA group for question A; $P = .013$; 2.99 \pm 1.45 in the DIE group versus 3.57 \pm 1.40 in the OVA group for question B; $P = .011$; Mann-Whitney U test).

Pelvic floor muscle morphometry

Women in the DIE group showed a smaller LHA at 3D transperineal ultrasound, compared to women in the OVA group (11.8 \pm 2.4 versus 10.9 \pm 2.4; $P = .019$; Student *t* Test), as reported in [Table 2](#). Pelvic floor muscle morphometry in women with superficial dyspareunia compared with women without superficial dyspareunia is reported in [Figure 1](#): the LHA was significantly narrower in women with superficial dyspareunia than in women without superficial dyspareunia

Table 2. Prevalence of different types of dyspareunia, questions A and B scores and levator hiatus area (LHA) at rest in the two groups.

	OVA group (n = 79)	DIE group (n = 81)	P value
No dyspareunia, n (%)	23/79 (29.1%)	12/81 (14.8%)	.028
Superficial dyspareunia, n (%)	47/79 (59.5%)	61/81 (75.3%)	.032
• Isolated	8/79 (10.1%)	10/81 (12.3%)	.657
• Concomitant with deep	39/79 (49.4%)	51/81 (62.9%)	.083
Isolated deep dyspareunia, n (%)	9/79 (11.4%)	8/81 (10.0%)	.756
Question A, mean ± SD Over the past 4 weeks how often did you experience pain during vaginal penetration occurring in/or around the vaginal entrance (superficial dyspareunia)?	3.15 ± 1.60	2.53 ± 1.54	.013
Question B, mean ± SD Over the past 4 weeks, how often did you experience deep pain felt in the vagina and in the pelvis following vaginal penetration (deep dyspareunia)?	3.57 ± 1.40	2.99 ± 1.45	.011
LHA at rest, cm ² , mean ± SD	11.8 ± 2.4	10.9 ± 2.4	.019

Categorical values were compared using χ^2 test. Female Sexual Function Index (FSFI) results were compared using Mann-Whitney U test. LHA was compared using Student t test.

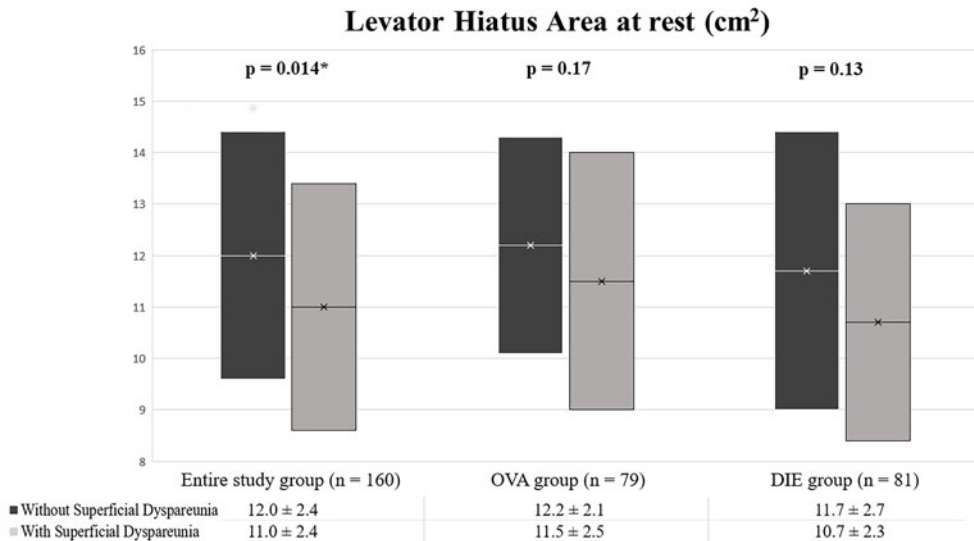


Figure 1. Levator Hiatus Area (LHA) at rest in women with and without superficial dyspareunia in the entire study group, in the OVA group and in the DIE group. In the entire study group LHA is significantly smaller in women experiencing superficial dyspareunia.

(11.0 ± 2.4 cm² versus 12.0 ± 2.4 cm², respectively; $P = .014$; Student t Test) in the entire study group. Moreover, a correlation between the frequency of superficial dyspareunia, assessed with question A, and LHA at rest in the entire study group was found (Spearman correlation $r = 0.208$, $P = .008$), while no correlation with question B analyzing deep dyspareunia was

Table 3. Correlation between frequency of superficial and deep dyspareunia (questions A and B scores) and levator hiatus area (LHA) at rest in the entire study group.

		Results mean \pm SD	Spearman correlation (r) between scores of question A and B and LHA at rest	P value
A. Over the past 4 weeks how often did you experience pain during vaginal penetration occurring in/or around the vaginal entrance (superficial dyspareunia)?	OVA GROUP	3.15 \pm 1.60	0.076	.50
	DIE GROUP	2.53 \pm 1.54	0.208	.07
	ENTIRE GROUP	2.83 \pm 1.61	0.208	.008
B. Over the past 4 weeks, how often did you experience deep pain felt in the vagina and in the pelvis following vaginal penetration (deep dyspareunia)?	OVA GROUP	3.57 \pm 1.40	0.001	.99
	DIE GROUP	2.99 \pm 1.45	0.111	.33
	ENTIRE GROUP	3.16 \pm 1.57	0.104	.19

detected. No correlation between exclusive OVA or DIE group and LHA was found for both questions A and B (Table 3).

Discussion

Sexually active women may experience painful intercourses due to endometriosis in 2–4% of cases and dyspareunia affects 32–70% of women with endometriosis, thus representing one of the most sensitive aspects of the disease (Barbara et al., 2017; De Graaff, Van Lankveld, Smits, Van Beek, & Dunselman, 2016; Pluchino et al., 2016). Most studies consider sexual pain only as “dyspareunia”, without discriminating deep from superficial dyspareunia, and without taking into account the localizations of the disease (Pluchino et al., 2016; Yong et al., 2017). Very little is known about the role of PFM in causing superficial dyspareunia, especially in women with endometriosis.

In this study, we detected a high prevalence of superficial dyspareunia in women both with DIE and isolated ovarian endometriosis. In particular, women with DIE seem to have a higher prevalence of superficial dyspareunia and more severe both superficial and deep dyspareunia NRS scores when compared to women with isolated ovarian endometriosis. In fact, women with only ovarian endometriosis usually have lower pain symptom intensity than women with DIE, including frequency and severity of dyspareunia (Chapron et al., 2012). Moreover, an increased density of nerve fibers together with perineural and intraneural invasion at immunohistochemistry have been detected in DIE lesions; this could explain the considerable intensity of the symptoms in DIE, including dyspareunia (Wang, Tokushige, Markham, & Fraser, 2009). Interestingly, in most cases superficial dyspareunia was concomitant with deep dyspareunia, in agreement with Yong et al (Yong et al., 2015). In these women, it is hard to explain if superficial dyspareunia precedes or follows deep dyspareunia. Nevertheless, isolated superficial dyspareunia was present in a small number of cases in the entire study group, with a higher prevalence in the DIE group, suggesting that the two symptoms may have different pathogenesis, as already reported (Shum et al., 2018).

Three-dimensional and four-dimensional transperineal ultrasound measuring LHA in both static and dynamic maneuvers was demonstrated as valid, reliable and noninvasive method for the assessment of pelvic morphometry and contractility, representing a valid tool comparable to digital palpation (Dietz, 2004; Van Delft, Thakar, & Sultan, 2015; Youssef et al., 2015). In this

study, we choose transperineal ultrasound because digital palpation could be biased by patient fear or pain reactions, particularly in women suffering from chronic pain (Morin et al., 2014), as women with endometriosis. According to our previous studies, women with DIE seem to have a smaller LHA at rest, suggesting an increased PFM tone. In the present study, women with superficial dyspareunia showed a smaller LHA at PFM evaluation than women without superficial dyspareunia in the entire study group, confirming the hypothesis that the ‘superficial dyspareunia’ symptom may be associated with PFM increased tone independently from the location of the endometriotic lesions. Moreover, a significant correlation between LHA at rest and the frequency of superficial dyspareunia was found, while correlation analysis stratified by diagnosis group failed statistical significance maybe due to the small sample sizes. Possible explanations of PFM hypertone in women with endometriosis may include relaxation and coordination anomalies of PFM and central and peripheral sensitization to pain with lowering nociceptive thresholds (Stratton, Khachikyan, Sinaii, Ortiz, & Shah, 2015; Yong, 2017).

Yong et al. demonstrated that endometriosis is a risk factor when deep and superficial dyspareunia coexist (Yong et al., 2015). Moreover, in another study of the same group, the prevalence of pelvic floor tenderness was 40% in a cohort of women with pelvic pain, rising to 60% in the subgroup of women with endometriosis (Yong, Mui, Allaire, & Williams, 2014). Mechanisms explaining the connection between endometriosis, pelvic floor tenderness and dyspareunia, both deep and superficial, are not yet clear. Our group has previously demonstrated that women with DIE may have an increased PFM tone evaluated with 3D transperineal ultrasound, when compared with both healthy women and women with exclusive ovarian endometriosis (Mabrouk et al., 2018; Raimondo et al., 2017).

To our knowledge, this is the first study that evaluates the presence of superficial dyspareunia and the association between the symptom and PFM morphometry in women with endometriosis. According to our results, during the complex evaluation of endometriotic symptoms, clinicians should be aware that increased pelvic floor tenderness may play a role in the physiopathology of pelvic pain and dyspareunia. Three-dimensional transperineal ultrasound may therefore be useful for the evaluation of PFM in women with endometriosis, especially in women with superficial dyspareunia, in order to identify the presence of an increased PFM tone. We strongly believe that, in women with endometriosis, the investigation of superficial dyspareunia related to PFM hypertone can help to identify which women can benefit from pelvic floor rehabilitation in a multidisciplinary approach to the disease.

The use of a noninvasive reliable technique to evaluate PFM morphometry, the histological confirmation of endometriosis and the analysis of volumes by operators blinded to clinical data, represent the main strengths of this study. The unpowered sample size of the study groups for all the outcomes represents the main limitation of the study. Other limits may be the absence of a control group, the non-inclusion of other populations that also showed deep or superficial dyspareunia and the lack of potential confounders factor as education, drugs, physical activity, marital status. Moreover, in literature few studies investigated the relationship between endometriosis and LHA and therefore sample size calculation was based on a single previous study conducted at our institution (Mabrouk et al., 2018). Another limitation could be represented by the absence of a validated questionnaire that focuses specifically on differentiating superficial from deep dyspareunia and by limiting the sample to sexually active women that could exclude women who are not active due to a dysfunction. Future research on superficial dyspareunia in a larger population of women with endometriosis is needed, as well as a validated and dedicated questionnaire to investigate the presence and characteristics of dyspareunia in women with endometriosis and the impact of this symptom on women’s quality of life.

In conclusion, superficial dyspareunia seems to be highly prevalent in women affected by endometriosis, especially DIE, and in most cases appears to be concomitant with deep dyspareunia. The frequency of superficial dyspareunia might be related to a smaller LHA at

transperineal ultrasound, suggesting an increased PFM tone in women affected by endometriosis reporting this symptom. The detection of superficial dyspareunia may represent a precious opportunity for a tailored approach for women with endometriosis, because this symptom probably deserves a dedicated therapeutic strategy. If confirmed, our findings could have promising clinical implications, paving the way for pelvic floor rehabilitation in women with endometriosis and superficial dyspareunia in a multidisciplinary approach to the disease.

Disclosure statement

The authors declare that they have no conflicts of interest and nothing to disclose.

References

- Barbara, G., Facchin, F., Buggio, L., Somigliana, E., Berlanda, N., Kustermann, A., & Vercellini, P. (2017). What is known and unknown about the association between endometriosis and sexual functioning: A Systematic review of the literature. *Reproductive Sciences*, 24(12), 1566–1576. doi:10.1177/1933719117707054
- Chapron, C., Santulli, P., de Ziegler, D., Noel, J.-C., Anaf, V., Streuli, I., ... Borghese, B. (2012). Ovarian endometrioma: Severe pelvic pain is associated with deeply infiltrating endometriosis. *Human Reproduction*, 27(3), 702. doi:10.1093/humrep/der462
- Cornillie, F. J., Oosterlynck, D., Lauweryns, J. M., & Koninckx, P. R. (1990). Deeply infiltrating pelvic endometriosis: Histology and clinical significance. *Fertility and Sterility*, 53(6), 978–983. doi:10.1016/S0015-0282(16)53570-5
- De Graaff, A. A., Van Lankveld, J., Smits, L. J., Van Beek, J. J., & Dunselman, G. A. J. (2016). Dyspareunia and depressive symptoms are associated with impaired sexual functioning in women with endometriosis, whereas sexual functioning in their male partners is not affected. *Human Reproduction*, 31(11), 2577–2586. doi:10.1093/humrep/dew215
- Di Donato, N., Montanari, G., Benfenati, A., Monti, G., Bertoldo, V., Mauloni, M., & Seracchioli, R. (2014). Do women with endometriosis have to worry about sex? *European Journal of Obstetrics & Gynecology and Reproductive Biology*, 179, 69–74. doi:10.1016/j.ejogrb.2014.05.022
- Dietz, H. P. (2004). Ultrasound imaging of the pelvic floor. Part II: Three-dimensional or volume imaging. *Ultrasound in Obstetrics and Gynecology*, 23(6), 615–625. doi:10.1002/uog.1072
- Dietz, H. P. (2017). Pelvic floor ultrasound: A review. *Clinical Obstetrics and Gynecology*, 60(1), 58–81. doi:10.1097/GRF.0000000000000264
- Filocamo, M. T., Serati, M., Li Marzi, V., Costantini, E., Milanese, M., Pietropaolo, A., ... Villari, D. (2014). The female sexual function index (FSFI): Linguistic validation of the Italian version. *The Journal of Sexual Medicine*, 11(2), 447–453. doi:10.1111/jsm.12389
- Fritzer, N., Haas, D., Oppelt, P., Renner, S., Hornung, D., Wölfler, M., ... Hudelist, G. (2013). More than just bad sex: Sexual dysfunction and distress in patients with endometriosis. *European Journal of Obstetrics & Gynecology and Reproductive Biology*, 169(2), 392–396. doi:10.1016/j.ejogrb.2013.04.001
- Guerrero, S., Condous, G., van den Bosch, T., Valentin, L., Leone, F. P. G., Van Schoubroeck, D., ... Timmerman, D. (2016). Systematic approach to sonographic evaluation of the pelvis in women with suspected endometriosis, including terms, definitions and measurements: A consensus opinion from the International Deep Endometriosis Analysis (IDEA) group. *Ultrasound in Obstetrics and Gynecology*, 48(3), 318–332. doi:10.1002/uog.15955
- Mabrouk, M., Raimondo, D., Del Forno, S., Baruffini, F., Arena, A., Benfenati, A., ... Seracchioli, R. (2018). Pelvic floor muscle assessment on three- and four-dimensional transperineal ultrasound in women with ovarian endometriosis with or without retroperitoneal infiltration: a step towards complete functional assessment. *Ultrasound Obstet Gynecol*, 52(2), 265–268. doi:10.1002/uog.18924
- Marinho, M. C. P., Magalhaes, T. F., Fernandes, L. F. C., Augusto, K. L., Brilhante, A. V. M., & Bezerra, L. R. P. S. (2017). Quality of life in women with endometriosis: An integrative review. *Journal of Women's Health*, 27(3), 399–408. doi:10.1089/jwh.2017.6397.
- Montanari, G., Di Donato, N., Benfenati, A., Giovanardi, G., Zannoni, L., Vicenzi, C., ... Seracchioli, R. (2013). Women with deep infiltrating endometriosis: Sexual satisfaction, desire, orgasm, and pelvic problem interference with sex. *The Journal of Sexual Medicine*, 10(6), 1559–1566. doi:10.1111/jsm.12133
- Morin, M., Bergeron, S., Khalifé, S., Mayrand, M. H., & Binik, Y. M. (2014). Morphometry of the pelvic floor muscles in women with and without provoked vestibulodynia using 4D ultrasound. *The Journal of Sexual Medicine*, 11(3), 776–785. doi:10.1111/jsm.12367

- Pluchino, N., Wenger, J. M., Petignat, P., Tal, R., Bolmont, M., Taylor, H. S., & Bianchi-Demicheli, F. (2016). Sexual function in endometriosis patients and their partners: Effect of the disease and consequences of treatment. *Human Reproduction Update*, 22(6), 762–774. doi:10.1093/humupd/dmw031
- Raimondo, D., Youssef, A., Mabrouk, M., Del Forno, S., Martelli, V., Pilu, G., ... Seracchioli, R. (2017). Pelvic floor muscle dysfunction on 3D/4D transperineal ultrasound in patients with deep infiltrating endometriosis: A pilot study. *Ultrasound in Obstetrics & Gynecology*, 50(4), 527–532. doi:10.1002/uog.17323
- Rogers, R. G., Pauls, R. N., Thakar, R., Morin, M., Kuhn, A., Petri, E., ... Lee, J. (2018). An International Urogynecological Association (IUGA)/International Continence Society (ICS) joint report on the terminology for the assessment of sexual health of women with pelvic floor dysfunction. *Neurourology and Urodynamics*, 37(4), 1220. doi:10.1002/nau.23508
- Rosen, R., Brown, C., Heiman, J., Leiblum, S., Meston, C., Shabsigh, R., ... D'Agostino, R. (2000). The Female Sexual Function Index (FSFI): A multidimensional self-report instrument for the assessment of female sexual function. *Journal of Sex & Marital Therapy*, 26(2), 191–208. 10.1080/009262300278597
- Seracchioli, R., Poggioli, G., Pierangeli, F., Manuzzi, L., Gualerzi, B., Savelli, L., ... Venturoli, S. (2007). Surgical outcome and long-term follow up after laparoscopic rectosigmoid resection in women with deep infiltrating endometriosis. *BJOG: An International Journal of Obstetrics & Gynaecology*, 114(7), 889–895. doi:10.1111/j.1471-0528.2007.01363.x
- Shum, L., Bedaiwy, M. A., & Yong, P. (2018). Deep dyspareunia and sexual quality of life in women with endometriosis. *Sexual Medicine*, 6(3), 224–233. doi:10.1016/j.esxm.2018.04.006
- Stratton, P., Khachikyan, I., Sinaii, N., Ortiz, R., & Shah, J. (2015). Association of chronic pelvic pain and endometriosis with signs of sensitization and myofascial pain. *Obstetrics & Gynecology*, 125(3), 719–728. doi:10.1097/AOG.0000000000000663
- Van Delft, K., Thakar, R., & Sultan, A. H. (2015). Pelvic floor muscle contractility: Digital assessment vs transperineal ultrasound. *Ultrasound in Obstetrics and Gynecology*, 45(2), 217–222.
- Wang, G., Tokushige, N., Markham, R., & Fraser, I. S. (2009). Rich innervation of deep infiltrating endometriosis. *Human Reproduction*, 24(4), 827–834. doi:10.1093/humrep/den464
- Yong, P. J. (2017). Deep dyspareunia in endometriosis: A proposed framework based on pain mechanisms and genito-pelvic pain penetration disorder. *Sexual Medicine Reviews*, 5(4), 495–507. doi:10.1016/j.sxmr.2017.06.005
- Yong, P. J., Mui, J., Allaire, C., & Williams, C. (2014). Pelvic floor tenderness in the etiology of superficial dyspareunia. *Journal of Obstetrics and Gynaecology Canada*, 36(11), 1002–1009. doi:10.1016/S1701-2163(15)30414-X
- Yong, P. J., Sadownik, L., & Brotto, L. A. (2015). Concurrent deep-superficial dyspareunia: Prevalence, associations, and outcomes in a multidisciplinary vulvodinia program. *The Journal of Sexual Medicine*, 12(1), 219–227. doi:10.1111/jsm.12729
- Yong, P. J., Williams, C., Yosef, A., Wong, F., Bedaiwy, M. A., Lisonkova, S., & Allaire, C. (2017). Anatomic sites and associated clinical factors for deep dyspareunia. *Sexual Medicine*, 5(3), e184–e195. doi:10.1016/j.esxm.2017.07.001
- Youssef, A., Montaguti, E., Sanlorenzo, O., Cariello, L., Salsi, G., Morganelli, G., ... Rizzo, N. (2016). Reliability of new three-dimensional ultrasound technique for pelvic hiatal area measurement. *Ultrasound in Obstetrics & Gynecology*, 47(5), 629–635. doi:10.1002/uog.14933
- Youssef, A., Montaguti, E., Sanlorenzo, O., Cariello, L., Awad, E. E., Pacella, G., ... Rizzo, N. (2015). A new simple technique for 3-dimensional sonographic assessment of the pelvic floor muscles. *Journal of Ultrasound in Medicine*, 34(1), 65–72. doi:10.7863/ultra.34.1.65

Appendix

Table A1. Questions to assess frequency of superficial (question A) and deep (question B) dyspareunia and relative scores.

Questions	1 pt	2 pt	3 pt	4 pt
A. Over the past 4 weeks how often did you experience pain during vaginal penetration occurring in/or around the vaginal entrance (superficial dyspareunia)?	Almost always or always	Most times (more than half the time)	Sometimes (about half the time)	A few times (less than half the time)
B. Over the past 4 weeks, how often did you experience deep pain felt in the vagina and in the pelvis following vaginal penetration (deep dyspareunia)?	Almost always or always	Most times (more than half the time)	Sometimes (about half the time)	A few times (less than half the time)