

Symptoms and classification of uterine adenomyosis, including the place of hysteroscopy in diagnosis

Stephan Gordts, M.D.,^{a,b} Grigoris Grimbizis, M.D., Ph.D.,^c and Rudi Campo, M.D.^{a,b}

^a Leuven Institute for Fertility & Embryology, Leuven, Belgium; ^b Life Expert Centre, Schipvaartstraat 4, Leuven, Belgium; and ^c 1st Department of Obstetrics and Gynecology, Aristotle University of Thessaloniki, Thessaloniki, Greece

Where histology used the presence of glands and/or stroma in the myometrium as pathognomonic for adenomyosis, imaging uses the appearance of the myometrium, the presence of striations, related to the presence of endometrial tissue within the myometrium, the presence of intramyometrial cystic structures and the size and asymmetry of the uterus to identify adenomyosis. Preliminary reports show a good correlation between the features detected by imaging and the histological findings. Symptoms associated with adenomyosis are abnormal uterine bleeding, pelvic pain (dysmenorrhea, chronic pelvic pain, dyspareunia), and impaired reproduction. However a high incidence of existing comorbidity like fibroids and endometriosis makes it difficult to attribute a specific pathognomonic symptom to adenomyosis. Heterogeneity in the reported pregnancy rates after assisted reproduction is due to the use of different ovarian stimulation protocols and absence of a correct description of the adenomyotic pathology. Current efforts to classify the disease contributed a lot in elucidated the potential characteristics that a classification system should be relied on. The need for a comprehensive, user friendly, and clear categorization of adenomyosis including the pattern, location, histological variants, and the myometrial zone seems to be an urgent need. With the uterus as a possible unifying link between adenomyosis and endometriosis, exploration of the uterus should not only be restricted to the hysteroscopic exploration of the uterine cavity but in a fusion with ultrasound. (*Fertil Steril*® 2018;109:380–8. ©2018 by American Society for Reproductive Medicine.)

Key Words: Adenomyosis, clinic, reproduction, classification, hysteroscopy

Discuss: You can discuss this article with its authors and other readers at <https://www.fertsterdialog.com/users/16110-fertility-and-sterility/posts/29040-25436>

Already described in 1860 by Karl Freiherr von Rokitansky (1) in the German literature as “fibrous tumors containing gland like structures that resemble endometrial glands,” in 1920 by Cullen (2) as “endometriosis with predominantly presence of fibromuscular tissue,” and in 1921 by Sampson (3) distinguishing three types of adenomyosis, adenomyosis received little attention in the later decades and remained for a long time the small appendix in books on endometriosis despite a high impact on women’s health. As adenomyosis could only be diagnosed definitively on histological specimens obtained after hysterectomy, the estimated incidence in retrospective studies varied between 5%–70% (4) and differences in prevalence are due to the criteria used.

A classical histological definition for adenomyosis is the invasion of the myometrium by endometrial glands and/or stroma, deeper than 2.5 mm from the endometrial–myometrial junction, accompanied by adjacent smooth muscle hyperplasia. It should be noted, however, that there are still different options in the definition of the disease ranging from the simple disruption of the endometrial–myometrial junction to a depth more than 8 mm or even relating the necessary depth of invasion to the myometrial thickness (5).

With the introduction and evolution of new imaging tools, adenomyosis moved from a histological diagnosis to a clinical entity. Ultrasound and magnetic resonance imaging (MRI) heralded a real turning point in the appreciation of adenomyosis as an important disorder

of the female reproductive tract. The systematic use of these technics enables visualization of the myometrial architecture’s distortions in a non-invasive way, distinguishing also the pathology of the outer and the inner myometrium or junctional zone (JZ). In contrast to the outer myometrium the JZ is hormonal dependent and is not only structurally but also functionally different from the outer myometrium. In women cycle dependent contractions are originated from the JZ in the late follicular phase in a cervical-fundal direction and in the late luteal phase in a fundal-cervical direction (6). A dysregulation of these contractions has been described in patients with endometriosis and adenomyosis resulting in dysperistalsis and hyperperistalsis, constituting the main mechanism of uterine auto-traumatization (7).

Despite the high prevalence of adenomyosis, the possibility of a pre-histologic identification and the severity of the symptoms interfering

Received December 12, 2017; revised January 3, 2018; accepted January 5, 2018.

S.G. has nothing to disclose. G.G. has nothing to disclose. R.C. has nothing to disclose.

Correspondence: Stephan Gordts, M.D., Life Expert Centre, Schipvaartstraat 4, 3000 Leuven, Belgium (E-mail: stephan.gordts@lifeexpertcentre.be).

Fertility and Sterility® Vol. 109, No. 3, March 2018 0015-0282/\$36.00

Copyright ©2018 American Society for Reproductive Medicine, Published by Elsevier Inc.

<https://doi.org/10.1016/j.fertnstert.2018.01.006>

with women's health, the pathogenesis of adenomyosis is not well understood (8). This lack of knowledge contributes to the lack of consensus on the classification. Like endometriosis, adenomyosis may present itself in various disguises, ranging from simple JZ thickening to focal, cystic, or diffuse lesions. However JZ thickening or hyperplasia and focal lesions of the junctional zone have to be interpreted carefully as changes of the JZ can be due to the cyclic hormonal variations and to the thickening of the JZ by aging (9, 10). Focal lesions are well circumscribed and can present either as a muscular or cystic lesion. Borders of diffuse lesions are not well circumscribed and can involve partially or entirely the posterior and/or anterior uterine wall resulting in an increased uterine and asymmetric volume.

The accuracy of the ultrasound in the diagnosis of adenomyosis is high with a mean sensitivity of 0.72 (95% confidence interval [CI] 0.65–0.79), specificity of 0.81 (95% CI 0.77–0.85), and area under the curve (AUC) of 0.85 (11); however, its diagnostic performance is biased by the experience of the examiner. With a higher diagnostic accuracy having a sensitivity of 77% (95% CI 67–85%), specificity of 89% (11), and AUC of 0.93, MRI, although more costly, has the advantage that it is less operator-dependent and diagnosis is based on objective image findings. MRI shows an excellent soft tissue differentiation with a clear identification of the junctional zone.

SYMPTOMS

It is hard to allocate one pathognomic symptom to the presence of adenomyosis. Symptoms associated with adenomyosis are pelvic pain (in the forms of dysmenorrhea, dyspareunia, and chronic pelvic pain), abnormal uterine bleeding, impaired reproductive potential, and feeling of swelling; however, approximately 30% patients with adenomyosis are asymptomatic (12). Furthermore, concomitant diseases with similar symptomatology are frequently present, masking the causal relationship between the disease and the symptoms; most frequent coexisting morbidities are endometriosis and fibroids. The incidence of adenomyosis as an isolated pathology is not clear, ranging from 38% to 64% (13).

Pain

Although a strict consensus on the association of adenomyosis and dysmenorrhea is debatable, the incidence of dysmenorrhea was reported between 50% and 93.4% (14–17). Women with leiomyomas and adenomyosis had an odds ratio of 3.4 (95% CI 1.8–6.4) to have more dysmenorrhea than women with only fibroids (17). A linear correlation between the extent of the adenomyosis and the severity of dysmenorrhea was described (16, 18). The problem of dysmenorrhea and pelvic pain in women with adenomyosis is not well understood, but prostaglandins may play an important role (19). In contrast with deep endometriosis, the presence of nerve fibers as a possible explanation for pain were described (20), the presence of nerve fibers in uterine adenomyosis is still a matter of debate (21, 22). Post hysterectomy specimens showed absence of nerves in areas of adenomyosis at the endometrial-myometrial nerve plexus. Focal proliferation of small-diameter nerve fibers was

observed at the margins of adenomyosis in some uteri (21). Uterine hyperperistalsis and the increased expression levels of oxytocin receptor in patients with adenomyosis may contribute to the severity of the dysmenorrhea (14).

Bleeding

In the presence of co-existing morbidity like uterine fibroids and inclusion of multiparous women, the causal effect of adenomyosis is hard to prove. However a higher incidence of abnormal uterine bleeding in nulliparous women with diffuse adenomyosis suggested by ultrasound examination was described by Pinzauti et al. (16). Naftalin et al. (13) reported a significant 22% increase in menstrual loss for each additional feature of adenomyosis [OR 1.21 (95% CI: 1.04–1.40)]. McCausland (23) in an attempt to estimate the amount of blood loss quantified the clot size in four categories. He found a statistically significant correlation between the depth of adenomyosis and the severity of abnormal uterine bleeding (AUB).

Although the genesis of abnormal uterine bleeding in cases of adenomyosis is difficult to prove, the PALM-COEIN classification (24) included adenomyosis as a cause of AUB in women of reproductive age. In hysterectomy specimens of patients with AUB, the prevalence of adenomyosis was 34.3%–49% (25, 26). In the absence of concomitant pathology, adenomyosis caused AUB in 27%–65% of patients (Table 1). AUB can be due to an increased uterine volume, increased vascularization, improper uterine contractions and increased production of estrogen and prostaglandins. In a series of 111 specimens Levgur et al. (27) found that there was no correlation between the number of adenomyotic foci and the severity of AUB, but that heavy menstrual bleeding correlated with the depth of penetration. There is no clear consensus in the literature on the correlation between adenomyosis and heavy menstrual bleeding. Meticulous recording of concomitant pathology (fibroids, high body mass index, presence of endometrial polyps) and of the different features visualized at ultrasound will be important to identify the most plausible explanation responsible for AUB.

Reproductive Potential

With the introduction of the concept of archimetra (28) and the use of more sophisticated techniques of direct imaging

TABLE 1

Adenomyosis proven by histology as the only pathology in presence of abnormal uterine bleeding.

Study	AUB
Owolabi et al. (85) (1977)	65
Bird et al. (68) (1972)	51.2
Ozkan et al. (86) (2011)	35
Weiss et al. (87) (2009)	27
Benson and Sneed (88) (1958)	38.4

Note: Data presented as percent. AUB = abnormal uterine bleeding.

Gordts. *Clinical aspects uterine adenomyosis. Fertil Steril* 2018.

adenomyosis became a different world. It became clear that the uterine myometrium was composed out of two structures: the outer myometrium and the inner myometrium also called sub endometrial layer or junctional zone. The latter is more akin to the endometrium and undergoes cycle dependent changes and is of müllerian origin while the outer myometrium is of non-müllerian, mesenchymal origin (28). Dysperistalsis of cycle dependent contractions of the junctional zone in patients with endometriosis and adenomyosis results in a more pronounced retrograde menstruation and a disturbed uterine tubal sperm transport (14, 29). In presence of a dysregulation of the myometrial structure and an altered endometrial function (30) there is accumulating evidence of a negative impact of adenomyosis on fertility.

Incidence of adenomyosis in patients with dysmenorrhea, menorrhagia, and infertility was reported to be as high as 50 % (31). By postponing pregnancy till a later stage in reproductive life span, an increased frequency of adenomyosis can be expected in patients consulting for fertility problems. Adenomyosis was reported in 24.6%–70% of patients with endometriosis depending on the definition of adenomyosis and on the severity of the endometriotic disease (14, 32, 33). In patients with deep endometriosis the prevalence of adenomyosis is 48.7%–66.3% (34, 35). Necropsy in baboons with long life infertility showed the presence of adenomyosis in all of them with the presence of endometriosis in 43% (36). Lower pregnancy rates were reported after colorectal surgery for endometriosis in the presence of adenomyosis (36–38).

As adenomyosis can be present in different sizes, localizations, and forms, a clear description of these lesions when reporting on results is mandatory. It is still unclear if lesions located in the inner myometrium will have the same impact on implantation and fertility as the lesions in the outer myometrium. Can junctional zone hyperplasia be considered as pathology and if so which cutoff level of JZ thickness is relevant? In addition to this heterogeneity in phenotypes of adenomyosis and the lack of a good description of the lesions, is the use of different ovarian stimulation protocols, making the reported pregnancy rates after in vitro fertilization highly controversial.

Reported results and understanding of adenomyosis is greatly hampered by a lack of agreed-upon terminology or consensus on the classification of the lesions (39, 40). In two recent meta-analyses (41, 42) adenomyosis was associated with a 30% decrease in the likelihood of pregnancy. Use of a gonadotropin-releasing hormone agonist long protocol for ovarian stimulation seems beneficial in patients undergoing assisted reproductive technology (41). By measuring the junctional zone thickness absence of pregnancy after IVF was reported in 95.8% of the patients when the average junctional zone thickness is > 7 mm and the maximal junctional zone thickness > 10 mm (43). However, it was proposed that JZ thickening has to be considered as a disruption of the endometrial/sub-endometrial myometrium unit different from adenomyosis and, thus, those two entities are different (44).

In patients with adenomyosis referred for oocyte donation, a lower implantation rate was not observed and there was a normal expression of the genes linked with implanta-

tion, however a higher miscarriage rate was reported (45). A two-fold increase in miscarriage rate was also reported in the meta-analysis of Vercellini et al. (41). Recently a higher incidence of miscarriages was reported in patients with endometriosis (46, 47); however it was not mentioned if these patients suffered also from adenomyosis. As in earlier publications, no higher abortion rates were mentioned (48).

Although not a first treatment option, spontaneous pregnancies are obtained after surgery. Partial or complete adenomyomectomy resulted in spontaneous pregnancy rates of respectively 46.9% and 49% and with an abortion rate of respectively 26.7% and 16.9% (49). The postoperative use of a hormonal suppression seems beneficial with increased pregnancy rates and lower recurrence rates compared to surgery alone (50, 51).

Pregnancy Outcome

Abnormal thickening of the JZ seems to be associated with impaired fertility. A recent study looking at pre-pregnancy images of ultrasound and/or MRI found a 1.83-fold increased risk of preterm delivery in patients with adenomyosis and a 1.98-fold risk for preterm premature rupture of membranes (PPROM) (52). As the JZ plays a unique role in the process of deep placentation (53, 54), it is questionable if pre-conception abnormality of the JZ predisposes a woman to impaired pregnancy outcome. In a retrospective study comparing 36 women diagnosed pre-conception with adenomyosis, pregnancy outcome was compared with a control group. The incidence of preterm delivery, preterm premature rupture of membranes, and small for gestational age for the adenomyosis patients versus the control group was respectively 41.7% versus 12.5%, 19.4% versus 4.2%, and 33.3% versus 10.4% (55).

As adenomyomectomy also removes myometrial tissue, the risk of uterine rupture is estimated to be increased compared to myomectomy. Only six papers describe the occurrence of uterine rupture during pregnancy after adenomyomectomy by laparotomy or laparoscopy (56, 57). The incidence, out of 97 cases of reported adenomyomectomy is estimated to be around 7%. Although spontaneous rupture and decidualisation of cystic lesions have been reported (58, 59), complications during pregnancy are rare.

Coexisting Conditions and Their Effect on Symptoms: Endometriosis and Fibroids

Adenomyosis was reported in 15%–57% of hysterectomy specimens of patients operated on for fibroids (60). On the other hand, fibroids were found in 23%–34% of patients with adenomyosis (13, 61). The presence of adenomyosis in women with fibroids is associated with more frequent and severe forms of pelvic pain (dysmenorrhea, dyspareunia, chronic pelvic pain) (60); thus, patients with more severe symptoms than that expected for the level of fibroids should be evaluated for the presence of adenomyosis.

A close relationship seems to exist between adenomyosis and endometriosis. In a retrospective study, women with adenomyosis were found to have a 4.5-fold increase in the presence of endometriosis compared to the control group of

women with fibroids (60). The presence of endometriosis in patients with adenomyosis has been reported as high as 80.6% (14), while adenomyosis was present in 79% of patients with endometriosis with a clear relation between the thickness of the junctional zone and the severity of endometriosis (62), although some concerns have been raised on this study due to the MRI protocol used to diagnose adenomyosis (63). In a recent study, the observed incidence of adenomyosis in patients with endometriosis was 65%, significantly higher than that in the endometriosis free group. Focal adenomyosis of the outer myometrium was significantly more frequent in the endometriosis-affected women especially in patients with deep endometriosis (35), supporting the hypothesis of a different pathogenesis between the inner and outer myometrium forms of adenomyosis (64). The maximum thickness of JZ in patients with endometriosis was also found to be significantly greater than in patients without endometriosis (65). Abnormalities of the JZ were present in 39.9% of patients with endometriosis versus only 22.5% in the control group (33). In a review of infertile patients operated on for deep infiltrating endometriosis, co-existent adenomyosis was found in 25.5% of them (66).

The differences in the observed incidence between the studies could be attributed to the different imaging methods and the criteria used for the diagnosis of the disease, the obligatory number of imaging features for establishing the presence as adenomyosis as well as differences in the forms of adenomyotic lesions. This underlines the need for standardization of imaging diagnostic criteria, especially those of ultrasound, and classification of the different forms of adenomyosis. However, despite the reported differences in the incidence of endometriosis in patients with adenomyosis and on the opposite of adenomyosis in patients with endometriosis, it is clear that endometriosis is a common finding in patients with adenomyosis sharing potentially part of the patient's symptomatology.

CURRENT CLASSIFICATION PROPOSALS AND FUTURE PERSPECTIVES

Use of sophisticated imaging techniques reveals different phenotypes of adenomyosis, ranging from a simple thickening or hyperplasia of the JZ to localized or even more exaggerated diffuse lesions involving most of the uterine myometrium with possible multi-focal cystic inclusions. However, it has to be noted that irregular thickening of the JZ, proposed as the MRI criterion for the diagnosis of diffuse adenomyosis, does not provide proof of mucosal invasion of the myometrium (44). Adenomyotic lesions could also differ depending on the predominance of the glandular (endometrial glands and/or stroma) or the muscular (smooth muscle hyperplasia) element of the disease. Furthermore, the degree of infiltration, as indicated by the density of adenomyotic lesions within the myometrium, might vary from patient to patient.

It is still unclear what the impact of the different forms is on the type and severity of the disease's clinical presentation. A recent meta-analysis showed a higher negative impact on pregnancy rates from diffuse forms of adenomyosis compared

to focal ones (42). The quantity of menstrual blood loss and the severity of menstrual pain were found to be positively related to the number of ultrasound features of adenomyosis, indicating a potential relation between symptoms and the disease's severity (13, 67). Furthermore, it is still unexplained which are the crucial parameters for making a woman symptomatic. Thus, recognition only of adenomyosis seems to be an unhelpful simplification in the presence of highly accurate diagnostic methods giving detailed information for various diseases' characteristics. As a result, nowadays, a reliable classification seems to be a clinical necessity.

A crucial point for any classification system is to choose the potentially important characteristics that should be adopted for the categorization. As adenomyosis is a histological entity of the uterine myometrium, anatomical and histological characteristics should be taken into account in the formation of the groups. On the other hand, as histological variants and anatomical distribution of the disease could be only studied in hysterectomy specimens, histology per se could not be used as a tool for classification for clinical use. The current availability of modern imaging techniques with an excellent correlation between histological and imaging findings, allows the use of anatomical and histological characteristics for categorization based on imaging findings and especially those of MRI (63).

A first attempt of classifying the disease was done in 1972 by Bird et al. (68) (Supplemental Table 1 (89)) based on the histological characteristics of the disease in the absence at that time of reliable imaging techniques. It was a grading system based on the depth and extent of the lesions. Grade I included sub-basal endometrial layers, grade II up to mid-myometrium, and grade III beyond mid myometrium with a slight, moderate, or marked degree of involvement. However the extent of the disease, the location and the uterine size was not taken into account. In another attempt at classification, based on MRIs (39), the thickness of the JZ was used as a basis with three proposed categories: JZ hyperplasia with a JZ thickness between 8 mm and 12 mm that could be partial or diffuse; adenomyosis with JZ >12 mm involving the outer myometrium with glandular foci to a different extent; and adenomyomas described as myometrial masses with indistinct margins. However, it is questionable if an enlargement of the JZ has to be considered as an adenomyotic lesion or a beginning of the disease. Tocci et al. (44) suggested the thickening of the JZ be considered as a sub-endometrial myometrial unit disruption disease, different from adenomyosis.

Localization of the disease was later used as the basis for categorization (64), introducing also the concept that inner and outer myometrium could be infiltrated independently and could be related to different pathogenic origin. Four subtypes are distinguished: intrinsic, extrinsic, intramural, and indeterminate. This concept was further supported by the findings of Chapron et al. (35). Pistofidis et al. (69) suggested a classification into diffuse, sclerotic, nodular, and cystic. For the needs of surgical treatment of the disease, later on, Grimbizis et al. (49) proposed a clinical histological classification system (Supplemental Table 1) and categorized adenomyosis into groups: diffuse including JZ (inner myometrium) thickening and outer myometrium extensive disease with

endometrial glands and stroma scattered throughout the uterine musculature (2); focal (equal not diffuse), including adenomyomas, defined as grossly circumscribed adenomyotic masses within the myometrium, and cystic adenomyosis; polypoid adenomyomas, including typical and atypical forms; and some special categories like those of adenomyomas of endocervical type and retroperitoneal adenomyosis.

It seems from the existing classification proposals, that different characteristics are potentially important for grouping. It is noteworthy to underline that any classification, in order to be clinically useful, should be clear in definitions and user-friendly. It is also reasonable to suggest that categorization should be based mainly on imaging findings mirroring the disease histology. Although MRI seems to have an obvious advantage, current improvements in ultrasound technology and efforts to clearly describe and categorize ultrasound features as well as to correlate them with histology (13, 70) could alter the place of ultrasound not only in diagnosis but also in classification of adenomyosis.

The extent of the myometrial involvement as well as the diffuse or the localized pattern of the disease seem to be important points for grouping, potentially related to symptomatology as well as to the decision-making treatment process, conservative or invasive (49). The myometrial zone is another parameter, as inner and outer myometrium are functionally different entities (39), potentially related to different symptomatology (abnormal bleeding, pain, and/or infertility), different phenotypes and different pathogenesis and relation to co-existent pathology, for example, endometriosis (35, 64). The role of disease location within the myometrium (anterior and posterior wall) is also important to be explored and its inclusion in a classification system gives the opportunity of a more detailed anatomical description of the disease distribution. The different histological variants characterized by the presence of mainly the glandular, muscular, or cystic element of the disease could also have a role in its clinical expression; obviously, in cases of polypoid adenomyomas, the presence of atypia is an important factor in the prognosis of the patient (49, 70, 72, 73). Thus, potentially important parameters to be included in a classification system could be: the affected area, inner or outer myometrium; the localization, anterior, posterior or fundus and the pattern; and size, diffuse or focal specified as muscular or cystic (Table 2). In relation to reproduction, a grading system based upon these parameters and the estimated severity of the disease could create homogeneity in the published reports. The International Federation of Gynecology and Obstetrics group is on the way to preparing a document for the classification of adenomyosis.

ATYPICAL POLYPOID ADENOMYOMAS

Atypical polypoid adenomyomas are infrequently diagnosed adenomyotic polypoid lesions of the endometrial cavity, presenting usually with abnormal uterine bleeding and characterized by irregular atypical glands with squamous metaplasia and a cellular, smooth muscle parenchyma; histologically, they resemble an infiltrating adenocarcinoma or a malignant mixed müllerian tumor. Although, they are consid-

TABLE 2

Potentially important parameters to be included in a classification system.

Parameter	Description
Affected area	Inner myometrium or outer myometrium
Localization	Anterior or posterior or fundus
Pattern	Diffuse or focal
Type	Muscular or cystic
Volume or size	Expressed as <1/3, <2/3, >2/3 or in cm

Gordts. Clinical aspects uterine adenomyosis. Fertil Steril 2018.

ered benign lesions, they could be associated with endometrial hyperplasia and endometrial adenocarcinoma (65, 66). Interestingly, they are also associated with high recurrence rates, exceeding 30%, and also subsequent hyperplasia and adenocarcinoma (71, 72).

If hysterectomy is not an option, hysteroscopic radical excision including the lesion, the adjacent endometrium, and the underlying myometrium together with random endometrial biopsies is recommended. Careful clinical ultrasound and hysteroscopic followup every 6 months is also needed (71).

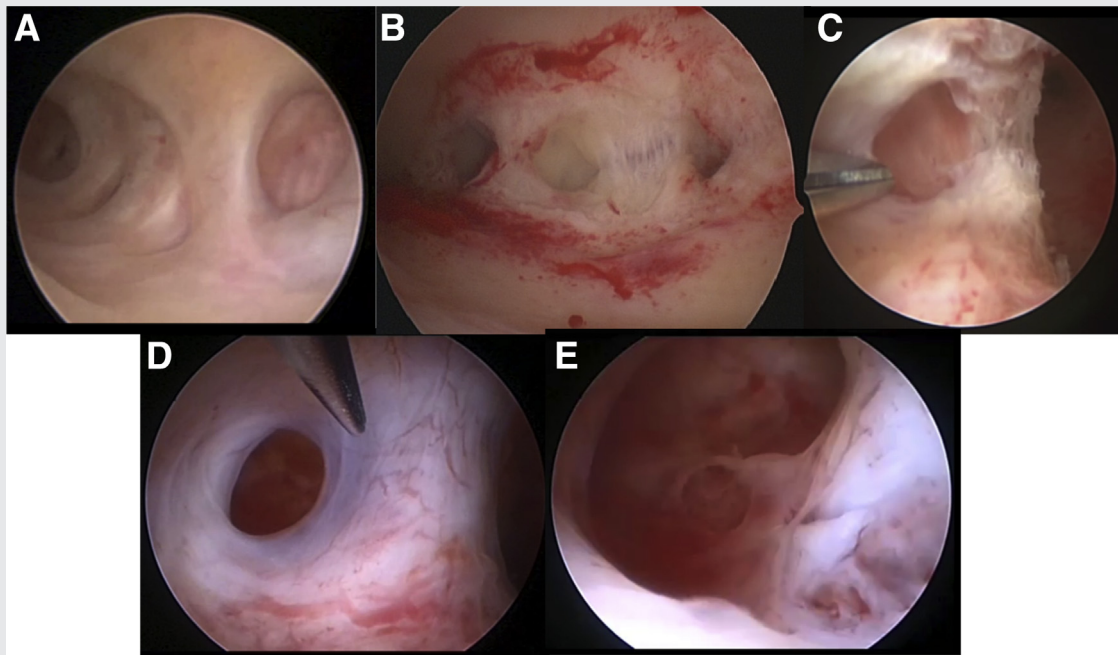
JUVENILE CYSTIC ADENOMYOSIS

Juvenile cystic adenomyosis (JCA) is a very rare form of adenomyosis in young women. Cullen (74) described the presence of solid and cystic structures of adenomyosis, defining the cystic structures as cysts filled with hemorrhagic fluid, not communicating with the uterine cavity, and lined by endometrium and surrounded by myometrium. Those cysts can vary in diameter, where some represented endometrial glands and others were isolated cysts within the intramural myometrium. Thus, as cystic adenomyosis should be considered the isolated cystic form of the disease and as JCA when present in women older than 30 years of age.

In a recent review (75) the presence of cystic adenomyosis was reported in 66 cases; of these, there were 43 cases of JCA (age group of 13–29 years old) with cyst diameters ranging between 10 mm–30 mm. Cysts increase in size at the moment of menstruation with a possible regression under hormonal suppression (76). In the young age group, the symptoms were severe dysmenorrhea starting early after onset of menstruation and resistant to medical therapy; on the other hand, the presence of adenomyotic cysts in the older age group caused mostly chronic pelvic pain and cysts were larger than 5 cm.

It should be, also, noted that adenomyotic cysts, especially the JCA forms, have to be distinguished from other congenital uterine anomalies such as a cavitated uterine rudimentary horn (77). Interestingly, in their review Acien et al. (77) interpreted most of the cases as accessory cavitated uterine mass containing functional endometrium. They suggested these lesions are of müllerian origin, representing ectopic müllerian tissue within the myometrium and, thus, supporting that they are a different entity and not adenomyosis.

FIGURE 1



Adenomyotic hysteroscopic images become pathognomic after sub-endometrial exploration: (A) visible endometrial defects on uterine septum; (B) after incision different cystic structures become visible; (C) incision of lateral wall of T-uterus reveals the presence of adenomyotic cyst; (D) formation of cyst, still small opening is present; and (E) opening of this defect shows the inner sight of the cyst.

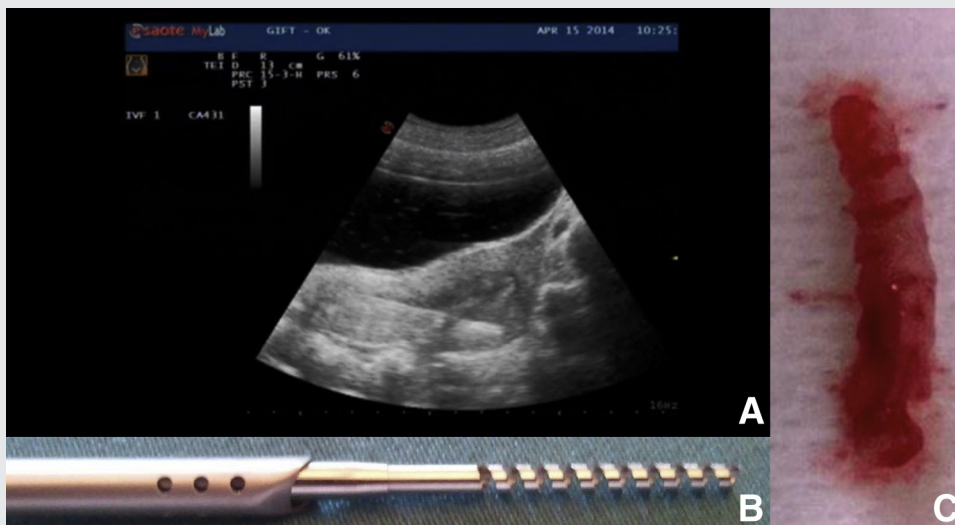
Gordts. Clinical aspects uterine adenomyosis. Fertil Steril 2018.

As benefits of medical therapy are doubtful, surgical removal preferably by laparoscopy has been proven successful. In selected cases, hysteroscopic removal can be a way forward.

HYSTEROSCOPY

Hysteroscopy offers the advantage of direct visualization of the uterine cavity. It has been proven that with the use of the modern small bored rigid hysteroscopes, using the

FIGURE 2



Use of utero-spirotome under ultrasound guidance: (A) ultrasound guided insertion of spirotome; (B) spirotome with 1 cm corkscrew; and (C) representative biopsy obtained after use of the spirotome.

Gordts. Clinical aspects uterine adenomyosis. Fertil Steril 2018.

atraumatic vaginoscopic route, and a watery distention medium the procedure is well tolerated in an outpatient environment (78). Moreover, the Trophy study (79) demonstrated no access failure or complications and 27 % of abnormalities in U.S. normal patients (79). A current drawback of hysteroscopy is the interobserver variation even between experts making it nearly impossible to perform correct multicenter studies to validate the importance of the different findings.

Hysteroscopic evaluation of the endometrial surface can detect changes, subtle lesions of which the pathological value is not yet proven but can be described as possible although not pathognomonic signs of adenomyotic changes in the myometrium.

Endometrial changes like hyper-vascularization, strawberry pattern, endometrial defects and submucosal hemorrhagic cysts are suggestive of adenomyosis (78, 80, 81) (Fig. 1). A cystic translucent area in the fundal area visualized by TVS, appearing as a bulging structure in the uterine cavity was described. Biopsy of the bed of the cyst was on histology diagnosed as adenomyosis (81). With the increasing evidence of the importance of the inner myometrium, uterine exploration in patients with infertility, abnormal uterine bleeding and pain should not be restricted to exploration of the uterine cavity but should include the exploration of the inner and outer myometrial structures. The Trophy hysteroscopy offers the possibility to enlarge the diagnostic procedure with ultrasound guided endomyometrial biopsies using the utero-spirotome device or using the hysteroscopic 5 French instruments. Hysteroscopic exploration of the sub endometrial myometrial provides pathognomonic signs of adenomyosis such as the neovascularization, chocolate dye filled cysts with endometrial implants on the pseudo-cystic wall (Supplemental Fig. 1).

A fusion of hysteroscopy and ultrasound imaging becomes mandatory. Such a hysteroscopic approach offers the possibility of obtaining endometrial/myometrial biopsies under visual control or ultrasound guidance. The diagnostic sheet of the Trophy hysteroscope can be used as a guide to insert the spirotome in the uterine cavity. Under ultrasound guidance, the corkscrew is positioned exactly towards the sonographic suspicious area. Once the position is agreed on, the cutting device is put forwards and a one cm trough cut biopsy is taken. Endo-myometrial biopsy showed a specificity of 78.46% with a low sensitivity of 54.32% the latter mostly related to the high amount of false negative in the cases of deep adenomyosis (82). On the contrary, ultrasound has a sensitivity of 72% (11). The Spirotome (Bioncise) offers the possibility to perform a direct forwarded biopsy and obtain a representative sample of tissue for further examination (83) (Fig. 2) including, when indicated, the different layers of endometrium, inner myometrium and outer myometrium. As continuity of infiltration of endometrial tissue into the myometrium seems important in the diagnosis of adenomyosis, performing a biopsy with the Spirotome offers the possibility for further research to distinct eventual differences in adenomyosis diagnosed in hysterectomy specimens and adenomyosis visualized by imaging in patients at reproductive age. With the direct access and the possibility of endomyome-

trial biopsies, the ultrasound images can now be correlated with the histological findings without the necessity of hysterectomy as in previously performed studies (84).

The hysteroscopic approach in the treatment of adenomyotic lesions (83) has the advantage of leaving the outer myometrium intact. In contrast to hysteroscopic resection of uterine myoma showing at postoperative control hysteroscopy a complete healing of the uterine cavity, postoperative control after adenomyomectomy or dissection of an adenomyotic cyst always shows a uterine defect. It is unclear if this is due to the infiltrative characteristic of the disease with a defective healing of the sub-endometrial zone.

CONCLUSIONS

Previously diagnosed on hysterectomy specimens, with the introduction of better performing indirect imaging techniques, adenomyosis became a clinical entity with the possibility of a diagnosis in a pre-surgical stage. With a poorly understood pathogenesis, the impact of the different phenotypes on pain, bleeding and reproduction stays unclear. Interpretation is rendered difficult because of the high incidence of concomitant pathology like endometriosis and fibroids. With a meticulous description of the images from ultrasound and MRI, the use of a standardized classification system and histological confirmation will enable us to better understand the impact of the disease. With increasing evidence of the importance of uterine integrity on reproduction, uterine exploration should not be restricted to the uterine cavity but should also include an exploration of the inner and outer myometrium. A fusion of hysteroscopy and ultrasound with the possibility of sub-endometrial tissue prelevation can contribute to a better understanding of the pathology and the impact on reproduction. Well-conducted studies are necessary.

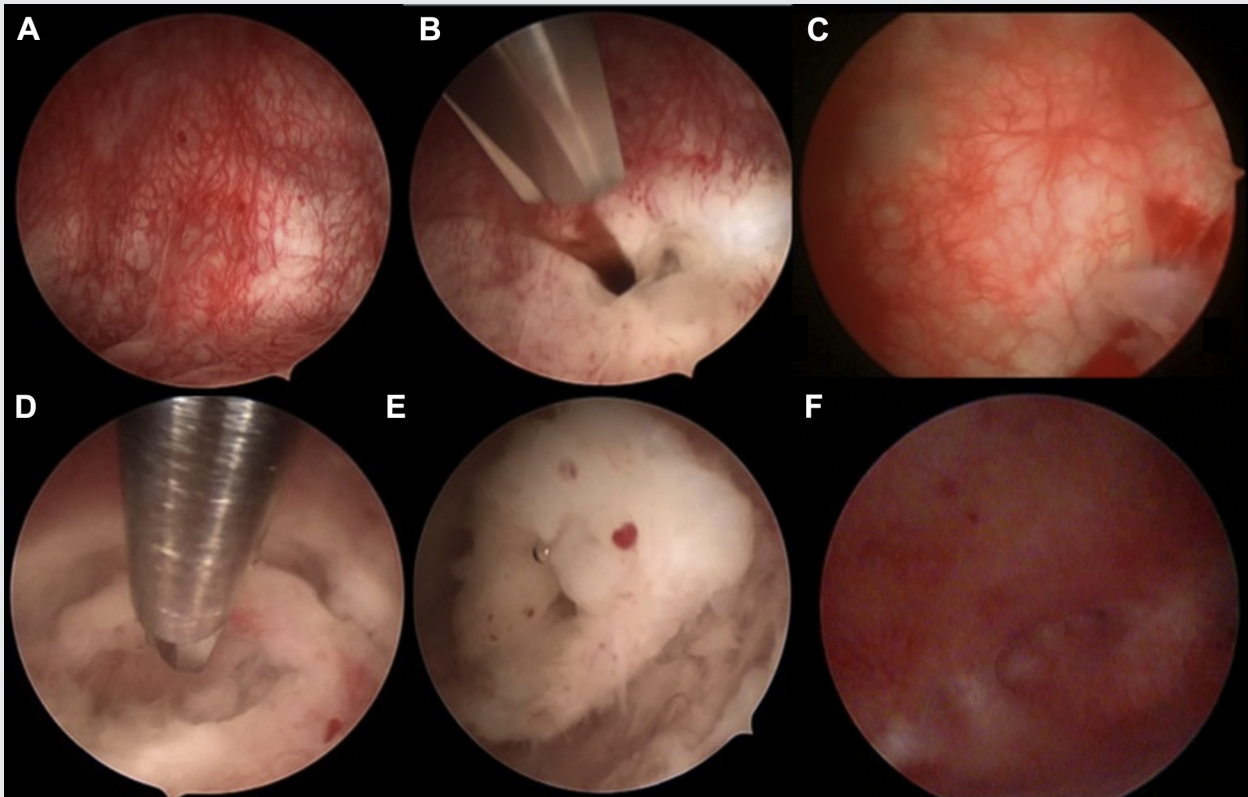
REFERENCES

1. Rokitansky C. Über uterusdrüsen-neubildung in uterus- und ovarial-sarcomen. *Zeitschr Gesellschaft der Aerzte Wien* 1860;16:577–81.
2. Cullen TS. The distribution of adenomyomata containing uterine mucosa. *Arch Surg* 1920;1:215–83.
3. Sampson JA. Perforating hemorrhagic (chocolate) cysts of the ovary: their importance and especially their relation to pelvic adenomas of the endometrial type. *Arch Surg* 1921;3:245–53.
4. Azziz R. Adenomyosis: current perspectives. *Obstet Gynecol Clin North Am* 1989;16:221–35.
5. Habiba M, Benagiano G. The incidence and clinical significance of adenomyosis. In: Habiba M, Benagiano G, eds. *Uterine adenomyosis*. Switzerland: Springer Cham.
6. Wildt L, Kissler S, Licht P, Becker W. Sperm transport in the human female genital tract and its modulation by oxytocin as assessed by hysterosalpingoscintigraphy, hysterotonography, electrohystero-graphy and Doppler sonography. *Hum Reprod Update* 1998;4:655–66.
7. Kissler S, Zangos S, Wiegatz I, Kohl J, Rody A, Gaetje R, et al. Utero-tubal sperm transport and its impairment in endometriosis and adenomyosis. *Ann N Y Acad Sci* 2007;1101:38–48.
8. García-Solares J, Donnez J, Donnez O, Dolmans M. Pathogenesis of uterine adenomyosis: invagination or metaplasia? *Fertil Steril* 2018;109:371–9.
9. Kunz G, Herbert M, Beil D, Huppert P, Leyendecker G. Adenomyosis as a disorder of the early and late human reproductive period. *Reprod Biomed Online* 2007;15:681–5.

10. Hauth EA, Jaeger HJ, Libera H, Lange S, Forsting M. MR imaging of the uterus and cervix in healthy women: determination of normal values. *Eur Radiol* 2007;17:734–42.
11. Champaneria R, Abedin P, Daniels J, Balogun M, Khan KS. Ultrasound scan and magnetic resonance imaging for the diagnosis of adenomyosis: systematic review comparing test accuracy. *Acta Obstet Gynecol Scand* 2010;89:1374–84.
12. Peric H, Fraser IS. The symptomatology of adenomyosis. *Best Pract Res Clin Obstet Gynaecol* 2006;20:547–55.
13. Naftalin J, Hoo W, Pateman K, Mavrelou D, Foo X, Jurkovic D. Is adenomyosis associated with menorrhagia? *Hum Reprod* 2014;29:473–9.
14. Leyendecker G, Bilgicildirim A, Inacker M, Staff T, Huppert P, Mall G, et al. Adenomyosis and endometriosis. Re-visiting their association and further insights into the mechanisms of auto-traumatisation. An MRI Study. *Arch Gynecol Obstet* 2015;291:917–32.
15. Li X, Liu X, Guo SW. Clinical profiles of 710 premenopausal women with adenomyosis who underwent hysterectomy. *J Obstet Gynaecol Res* 2014;40:485–94.
16. Pinzauti S, Lazzeri L, Tosti C, Centini G, Orlandini C, Luisi S, et al. Transvaginal sonographic features of diffuse adenomyosis in 18–30-year-old nulligravid women without endometriosis: association with symptoms. *Ultrasound Obstet Gynecol* 2015;46:730–6.
17. Taran FA, Wallwiener M, Kabashi D, Rothmund R, Rall K, Kraemer B, et al. Clinical characteristics indicating adenomyosis at the time of hysterectomy: a retrospective study in 291 patients. *Arch Gynecol Obstet* 2012;285:1571–6.
18. Kissler S, Zangos S, Kohl J, Wiegatz I, Rody A, Gätje R, et al. Duration of dysmenorrhoea and extent of adenomyosis visualised by magnetic resonance imaging. *Eur J Obstet Gynecol Reprod Biol* 2008;137:204–9.
19. Harel Z. Dysmenorrhea in adolescents and young adults: from pathophysiology to pharmacological treatments and management strategies. *Expert Opin Pharmacother* 2008;9:2661–72.
20. Anaf V, Simon P, El Nakadi I, Fayt I, Buxant F, Simonart T, et al. Relationship between endometriotic foci and nerves in rectovaginal endometriotic nodules. *Hum Reprod* 2000;15:1744–50.
21. Quinn M. Uterine innervation in adenomyosis. *J Obstet Gynaecol* 2007;27:287–91.
22. Zhang X, Lu B, Huang X, Xu H, Zhou C, Lin J. Innervation of endometrium and myometrium in women with painful adenomyosis and uterine fibroids. *Fertil Steril* 2010;94:730–7.
23. McCausland AM. Hysteroscopic myometrial biopsy: its use in diagnosing adenomyosis and its clinical application. *Am J Obstet Gynecol* 1992;166:1619–28.
24. Munro MG, Critchley HO, et al. FIGO classification system (PALM-COEIN) for causes of abnormal uterine bleeding in non-gravid women of reproductive age. *Int J Gynaecol Obstet* 2011;113:3–13.
25. Pervez SN, Javed K. Adenomyosis among samples from hysterectomy due to abnormal uterine bleeding. *J Ayub Med Coll Abbottabad* 2013;25:68–70.
26. Mobarakeh MD, Maghsudi A, Rashidi I. Adenomyosis among samples from hysterectomy due to abnormal uterine bleeding in Ahwaz, southern Iran. *Adv Biomed Res* 2012;1:49.
27. Levgur M, Abadi MA, Tucker A. Adenomyosis: symptoms, histology, and pregnancy terminations. *Obstet Gynecol* 2000;95:688–91.
28. Noe M, Kunz G, Herberich M, Mall G, Leyendecker G. The cyclic pattern of the immune-cytochemical expression of oestrogen and progesterone receptors in human myometrial and endometrial layers: characterization of the endometrial-subendometrial unit. *Hum Reprod* 1999;14:190–7.
29. Kissler S, Siebzehnuebl E, Kohl J, Mueller A, Hamscho N, Gaetje R, et al. Uterine contractility and directed sperm transport assessed by hysterosalpingoscintigraphy (HSSG) and intrauterine pressure (IUP) measurement. *Acta Obstet Gynecol Scand* 2004;83(4):369–74.
30. Campo S, Campo V, Benagiano G. Infertility and adenomyosis. *Obstet Gynecol Int* 2012;2012:786132.
31. Brosens JJ, de Souza NM, Barker FG. Uterine junctional zone: function and disease. *Lancet* 1995;346:558–60.
32. Kunz G, Beil D, Huppert P, Leyendecker G. Structural abnormalities of the uterine wall in women with endometriosis and infertility visualized by vaginal sonography and magnetic resonance imaging. *Hum Reprod* 2000;15:76–82.
33. Larsen SB, Lundorf E, Forman A, Dueholm M. Adenomyosis and junctional zone changes in patients with endometriosis. *Eur J Obstet Gynecol Reprod Biol* 2011;157:206–11.
34. Lazzeri L, Di Giovanni A, Exacoustos C, Tosti C, Pinzauti S, Malzoni M, et al. Preoperative and postoperative clinical and transvaginal ultrasound findings of adenomyosis in patients with deep infiltrating endometriosis. *Reprod Sci* 2014;21:1027–33.
35. Chapron C, Tosti C, Marcellin L, Bourdon M, Lafay-Pillet MC, Millischer AE, et al. Relationship between the magnetic resonance imaging appearance of adenomyosis and endometriosis phenotypes. *Hum Reprod* 2017;32:1393–401.
36. Barrier BF, Malinowski MJ, Dick EJ Jr, Hubbard GB, Bates GW. Adenomyosis in the baboon is associated with primary infertility. *Fertil Steril* 2004;82(Suppl 3):1091–4.
37. Ballester M, d'Argent EM, Morcel K, Belaisch-Allart J, Nisolle M, Daraï E. Cumulative pregnancy rate after ICSI-IVF in patients with colorectal endometriosis: results of a multicentre study. *Hum Reprod* 2012;27:1043–9.
38. Daraï E, Marpeau O, Thomassin I, Dubernard G, Barranger E, Bazot M. Fertility after laparoscopic colorectal resection for endometriosis: preliminary results. *Fertil Steril* 2005;84:945–50.
39. Gordts S, Brosens JJ, Fusi L, Benagiano G, Brosens I. Uterine adenomyosis: a need for uniform terminology and consensus classification. *Reprod Biomed Online* 2008;17:244–8.
40. Bazot M, Daraï E. Role of transvaginal sonography and magnetic resonance imaging in the diagnosis of uterine adenomyosis. *Fertil Steril* 2018;109:389–97.
41. Vercellini P, Consonni D, Drudi D, Bracco B, Frattaruolo MP, Somigliana E. Uterine adenomyosis and in vitro fertilization outcome: a systematic review and meta-analysis. *Hum Reprod* 2014;29:964–77.
42. Younes G, Tulandi T. Effects of adenomyosis on in vitro fertilization treatment outcomes: a meta-analysis. *Fertil Steril* 2017;108:483–90.
43. Maubon A, Faury A, Kapella M, Pouquet M, Piver P. Uterine junctional zone at magnetic resonance imaging: a predictor of in vitro fertilization implantation failure. *J Obstet Gynaecol Res* 2010;36:611–8.
44. Tocci A, Greco E, Ubaldi FM. Adenomyosis and 'endometrial-subendometrial myometrium unit disruption disease' are two different entities. *Reprod Biomed Online* 2008;17:281–91.
45. Martínez-Conejero JA, Morgan M, Montesinos M, Fortuño S, Meseguer M, Simón C, et al. Adenomyosis does not affect implantation, but is associated with miscarriage in patients undergoing oocyte donation. *Fertil Steril* 2011;96:943–50.
46. Pallacks C, Hirchenhain J, Krüssel JS, Fehm TN, Fehr D. Endometriosis doubles odds for miscarriage in patients undergoing IVF or ICSI. *Eur J Obstet Gynecol Reprod Biol* 2017;213:33–8.
47. Minebois H, De Souza A, Mezan de Malartic C, Agopiantz M, Guillet May F, Morel O, et al. Endometriosis and miscarriage: Systematic review. *Gynecol Obstet Fertil Senol* 2017;45:393–9.
48. Leonardi M, Papaleo E, Reschini M, Pagliardini L, Benaglia L, Candotti G, et al. Risk of miscarriage in women with endometriosis: insights from in vitro fertilization cycles. *Fertil Steril* 2016;106:386–92.
49. Grimbizis GF, Mikos T, Tarlatzis B. Uterus-sparing operative treatment for adenomyosis. *Fertil Steril* 2014;101:472–87.
50. Wang PH, Fuh JL, Chao HT, Liu WM, Cheng MH, Chao KC. Is the surgical approach beneficial to subfertile women with symptomatic extensive adenomyosis? *J Obstet Gynaecol Res* 2009;35:495–502.
51. Guy MM, Ying WZ, Yan WX, Hui FZ, Hai WX, Ping LY. Effectiveness of treatment for infertility using clinical investigation of laparoscopy cytoreductive surgery combined with gestrinone in adenomyosis. *Gynecol Surg* 2016;13:451–6.
52. Juang CM, Chou P, Yen MS, Twu NF, Horng HC, Hsu WL. Adenomyosis and risk of preterm delivery. *BJOG* 2006;114:165–9.
53. Brosens I, Derwig I, Brosens J, Fusi L, Benagiano G, Pijnenborg R. The enigmatic uterine junctional zone: the missing link between reproductive disorders and major obstetrical disorders? *Hum Reprod* 2010;25:569–74.

54. Brosens I, Pijnenborg R, Benagiano G. Defective myometrial spiral artery remodeling as a cause of major obstetrical syndromes in endometriosis and adenomyosis. *Placenta* 2013;34:100–5.
55. Mochimaru A, Aoki S, Oba MS, Kurasawa K, Takahashi T, Hirahara F. Adverse pregnancy outcomes associated with adenomyosis with uterine enlargement. *J Obstet Gynaecol Res* 2015;41:529–33.
56. Nagao Y, Osato K, Kubo M, Kawamura T, Ikeda T, Yamawaki T. Spontaneous uterine rupture in the 35th week of gestation after laparoscopic adenomyomectomy. *Int Med Case Rep* 2015;17:1–4.
57. Ukita S, Koshiyama M, Yamaguchi A, Ueda M, Ukita M, Hishikawa K, et al. Total uterine rupture during pregnancy after an adenomyomectomy. *Am J Case Rep* 2011;12:106–9.
58. Shitano F, Kido A, Fujimoto K, Umeoka S, Himoto Y, Kiguchi K, et al. Decidualized adenomyosis during pregnancy and post delivery: three cases of magnetic resonance imaging findings. *Abdom Imaging* 2013;38:851–7.
59. Nikolaou M, Kourea HP, et al. Spontaneous uterine rupture in a primigravid woman in the early third trimester attributed to adenomyosis: a case report and review of the literature. *J Obstet Gynaecol Res* 2013;39:727–32.
60. Taran FA, Weaver AL, Coddington CC, Stewart EA. Understanding adenomyosis: a case control study. *Fertil Steril* 2010;94:1223–8.
61. Naftalin J, Hoo W, Pateman K, Mavrelis D, Holland T, Jurkovic D. How common is adenomyosis? A prospective study of prevalence using transvaginal ultrasound in a gynaecology clinic. *Hum Reprod* 2012;27:3432–9.
62. Kunz G, Beil D, Huppert P, Noe M, Kissler S, Leyendecker G. Adenomyosis in endometriosis—prevalence and impact on fertility. Evidence from magnetic resonance imaging. *Hum Reprod* 2005;20:2309–16.
63. Bazot M, Fiori O, Darai E. Adenomyosis in endometriosis—prevalence and impact on fertility. *Evid Magn Reson Imaging Hum Reprod* 2006;21:1101–2.
64. Kishi Y, Suginami H, Kuramori R, Yabuta M, Suginami R, Taniguchi F. Four subtypes of adenomyosis assessed by magnetic resonance imaging and their specification. *Am J Obstet Gynecol* 2012;207:114.
65. Exacoustos C, Luciano D, Corbett B, De Felice G, Di Felicianantonio M, Luciano A, et al. The uterine junctional zone: a 3-dimensional ultrasound study of patients with endometriosis. *Am J Obstet Gynecol* 2013;209:248.
66. Vercellini P, Consonni D, Barbara G, Buggio L, Frattaruolo MP, Somigliana E. Adenomyosis and reproductive performance after surgery for rectovaginal and colorectal endometriosis: a systematic review and meta-analysis. *Reprod Biomed Online* 2014;28:704–13.
67. Naftalin J, Hoo W, Nunes N, Holland T, Mavrelis D, Jurkovic D. Association between ultrasound features of adenomyosis and severity of menstrual pain. *Ultrasound Obstet Gynecol* 2016;47:779–83.
68. Bird CC, McElin TW, Manalo-Estrella P. The elusive adenomyosis of the uterus revisited. *Am J Obstet Gynecol* 1972;112:583–93.
69. Pistofidis G, Makrakis E, Koukoura O, Bardis N, Balinakos P, Anaf V. Distinct types of uterine adenomyosis based on laparoscopic and histopathologic criteria. *Lin Exp Obstet Gynecol* 2014;41:113–8.
70. Van den Bosch T, Dueholm M, Leone FP, Valentin L, Rasmussen CK, Votino A, et al. Terms, definitions and measurements to describe sonographic features of myometrium and uterine masses: a consensus opinion from the Morphological Uterus Sonographic Assessment (MUSA) group. *Ultrasound Obstet Gynecol* 2015;46:284–98.
71. Grimbizis GF, Mikos T, Miliaras D, Kioussis G, Theodoridis TD, Tsolakidis D, et al. Management of atypical polypoid adenomyomas. A case series. *Eur J Obstet Gynecol Reprod Biol* 2017;215:1–5.
72. Heatley MK. Atypical polypoid adenomyoma: a systematic review of the English literature. *Histopathology* 2006;48:609–10.
73. Němejčová K, Kenny SL, Laco J, Škapa P, Staněk L, Zikán M, et al. Atypical Polypoid adenomyoma of the uterus: an immunohistochemical and molecular study of 21 cases. *Am J Surg Pathol* 2015;39:1148–55.
74. Cullen TS. Adenomyoma of the uterus. Philadelphia: W.B. Saunders; 1908.
75. Brosens I, Gordts S, Habiba M, Benagiano G. uterine cystic adenomyosis: a disease of younger women. *J Pediatr Adolesc Gynecol* 2015;28:420–6.
76. Fisseha S, Smith YR, Kumetz LM, Mueller GC, Hussain H, Quint EH. Cystic myometrial lesion in the uterus of an adolescent girl. *Fertil Steril* 2006;86:716–8.
77. Acien P, Acien M, Fernandez F, Mayol JM, Aranda I. The cavitated accessory uterine mass: a Mullerian anomaly in women with an otherwise normal uterus. *Obstet Gynecol* 2010;116:1101.
78. Molinas CR, Campo R. Office hysteroscopy and adenomyosis. *Best Pract Res Clin Obstet Gynaecol* 2006;20:557–67.
79. El-Toukhy T, Campo R, Khalaf Y, Tabanelli C, Gianaroli L, Gordts SS, et al. Hysteroscopy in recurrent in-vitro fertilisation failure (TROPHY): a multicentre, randomised controlled trial. *Lancet* 2016;387:2614–21.
80. Di Spiezio Sardo A, Calagna G, Santangelo F, Zizolfi B, Tanos V, Perino A, et al. The role of hysteroscopy in the diagnosis and treatment of adenomyosis. *BioMed Res Int* 2017;2017. Article ID 2518396. <https://doi.org/10.1155/2017/2518396>.
81. Puttemans P, Molinas R, Gordts S, Peperstraete L, Campo R, Brosens I, et al. Hysteroscopic images of an isolated lesion of unknown origin in a young infertile patient. *J Minim Invasive Gynecol* 2005;12:104–5.
82. Dakhly DM, Abdel Moety GA, Saber W, Gad Allah SH, Hashem AT, Abdel Salam LO. Accuracy of hysteroscopic endomyometrial biopsy in diagnosis of adenomyosis. *J Minim Invasive Gynecol* 2016;23:364–71.
83. Gordts S, Campo R, Brosens I. Hysteroscopic diagnosis and excision of myometrial cystic adenomyosis. *Gynecol Surg* 2014;11:273–8.
84. Luciano DE, Exacoustos C, Albrecht L, LaMonica R, Proffer A, Zupi E, et al. Three-dimensional ultrasound in diagnosis of adenomyosis: histologic correlation with ultrasound targeted biopsies of the uterus. *J Minim Invasive Gynecol* 2013;20:803–10.
85. Owolabi TO, Strickler RC. Adenomyosis: a neglected diagnosis. *Obstet Gynecol* 1977;50:424–7.
86. Özkan ZS, Kumbak B, Cilgin H, Simsek M, Turk BA. Coexistence of adenomyosis in women operated for benign gynecological diseases. *Gynecol Endocrinol* 2012;28:212–5.
87. Weiss G, Maseelall P, Schott LL, Brockwell SE, Schocken M, Johnston JM. Adenomyosis a variant, not a disease? Evidence from hysterectomized menopausal women in the Study of Women's Health Across the Nation (SWAN). *Fertil Steril* 2009;91:201–6.
88. Benson RC, Sneedden VD. Adenomyosis: a reappraisal of symptomatology. *Am J Obstet Gynecol* 1958;76:1044–61.
89. Vercellini P, Vigano P, Somigliana E, et al. Adenomyosis: epidemiological factors. *Best Pract Res Clin Obstet Gynaecol* 2006;20:465–77.

SUPPLEMENTAL FIGURE 1



Adenomyosis (sub-endometrial cystic structures): (A) by lowering intra-uterine pressure abnormal vascularization and cystic bulging hiding adenomyotic cyst can clearly be identified; (B) opening cyst with scissors with outflow of chocolate content; (C) insight view of adenomyotic cyst; (D) progressive dissection of cyst with scissors; (E) view of dissected cyst, arrow showing the opening of initial access with scissors; and (F) postoperative control after 12 weeks (defect is still visible).

Gordts. *Clinical aspects uterine adenomyosis. Fertil Steril* 2018.