

Accepted Manuscript

Title: Intraoperative Enhanced Imaging for Detection of Endometriosis: A Systematic Review of the Literature

Authors: Mahdi Al-Taher, Shugi Hsien, Rutger M. Schols, Nehalennia Van Hanegem, Nicole D. Bouvy, Gerard A.J. Dunselman, Laurents P.S. Stassen



PII: S0301-2115(18)30115-5
DOI: <https://doi.org/10.1016/j.ejogrb.2018.03.020>
Reference: EURO 10270

To appear in: *EURO*

Received date: 16-9-2017
Revised date: 8-3-2018
Accepted date: 12-3-2018

Please cite this article as: Al-Taher Mahdi, Hsien Shugi, Schols Rutger M, Hanegem Nehalennia Van, Bouvy Nicole D, Dunselman Gerard AJ, Stassen Laurents P.S. Intraoperative Enhanced Imaging for Detection of Endometriosis: A Systematic Review of the Literature. *European Journal of Obstetrics and Gynecology and Reproductive Biology* <https://doi.org/10.1016/j.ejogrb.2018.03.020>

This is a PDF file of an unedited manuscript that has been accepted for publication. As a service to our customers we are providing this early version of the manuscript. The manuscript will undergo copyediting, typesetting, and review of the resulting proof before it is published in its final form. Please note that during the production process errors may be discovered which could affect the content, and all legal disclaimers that apply to the journal pertain.

Title: Intraoperative Enhanced Imaging for Detection of Endometriosis: A Systematic Review of the Literature

Authors

Mahdi Al-Taher, MD¹

Shugi Hsien, MD¹

Rutger M. Schols, MD, PhD^{1,3}

Nehalennia Van Hanegem, MD, PhD²

Nicole D. Bouvy, MD, PhD¹

Gerard A.J. Dunselman, MD, PhD²

Laurents P.S. Stassen, MD, PhD¹

Author affiliations

1. Department of Surgery, Maastricht University Medical Center, Maastricht, The Netherlands
2. Maastricht University Medical Center, Department of Obstetrics & Gynaecology, Research Institute GROW, Maastricht, The Netherlands
3. Department of Plastic, Reconstructive, and Hand Surgery, Maastricht University Medical Center, Maastricht, The Netherlands

Correspondence to

M. Al-Taher, MD

Department of Surgery, Maastricht University Medical Center

Address: P. Debyelaan 25, 6229 HX Maastricht, The Netherlands

Telephone: 0031-649749942

Fax: 0031-433875473

Email: mahdialtaher@yahoo.com

Condensation

The use of contrast-based enhanced imaging during laparoscopy is promising and can provide a better visualization of peritoneal endometriosis.

ACCEPTED MANUSCRIPT

Intraoperative Enhanced Imaging for Detection of Endometriosis: A Systematic Review of the Literature

Mahdi Al-Taher, MD¹, Shugi Hsien, MD¹, Rutger M. Schols, MD, PhD^{1,3}, Nehalennia Van Hanegem, MD, PhD², Nicole D. Bouvy, MD, PhD¹, Gerard A.J. Dunselman, MD, PhD², Laurents P.S. Stassen, MD, PhD¹

Standard Abstract:

The diagnosis of peritoneal endometriosis during laparoscopy may be difficult due to the polymorphic aspects of the lesions. Enhanced imaging using contrast agents has potential to provide a better identification of peritoneal endometriosis. The aim of this systematic review is to provide an overview of the literature on what is known about the intraoperative laparoscopic visual enhancement of peritoneal endometriosis using contrast agents.

A systematic review was done of studies about enhanced imaging during laparoscopy for endometriosis using contrast agents. Clinical studies which contained a description of imaging with a contrast agent and also reported visual findings of endometriosis during laparoscopy, were included.

Nine suitable studies were identified. Intraoperative visualization of endometriosis was analyzed with or without histologic confirmation. Four studies evaluated 5-aminolevulinic acid-induced fluorescence (5-ALA), 1 study evaluated indigo carmine, 2 studies evaluated methylene blue (MB), 1 study evaluated indocyanine green (ICG) and 1 study evaluated so-called bloody peritoneal fluid painting. All studies, with a combined total of 171 included patients, showed potential of enhanced visibility of endometriosis using contrast agents. A combined total of 7 complications, all related to the use of 5-ALA, were reported. We conclude that the use of contrast-based enhanced imaging during laparoscopy is promising and that it can provide a better visualization of peritoneal endometriosis. However, based on the limited data no technique of preference can yet be identified.

Keywords Endometriosis • Minimal Invasive Surgery * Laparoscopy • Contrast media • Coloring agents • systematic review

INTRODUCTION

Endometriosis, defined as the presence of endometrial tissue outside the uterine cavity, is a common disease affecting 10-15% of women of reproductive age and up to 90% of women with pelvic pain (1-5). Women with endometriosis have a reduced quality of life and are at higher risk of several chronic diseases, which causes a significant burden not only to the women involved but also to society (6-9). Furthermore, the elevated presence of anxiety and depressive symptoms suggests the need for psychological support (10). The gold standard for diagnosis of endometriosis is a combination of a diagnostic laparoscopy and histologic confirmation (11, 12). Laparoscopic ablation/excision is found to be effective in endometriosis-related infertility (13) and in pain reduction (14). It is also known that postoperative recurrence of endometriosis is likely due to incomplete resection during the initial surgery (15, 16). Therefore, an effective resection is very important. It is reported, however, that the appearance of peritoneal endometriosis can vary considerably, ranging from colorless blebs (non-pigmented subtle endometriosis), to hypervascularized areas and the classically described black and powder-burned lesions (pigmented endometriosis) (17, 18). During histology, the subtle lesions may appear to be normal peritoneum, illustrating the potential difficulty in identifying them correctly (2, 17, 19). The revised American Society of Reproductive Medicine classification categorizes the lesions as red (red, red-pink, and clear lesions), white (white, yellow-brown, and peritoneal defects), and black (black and blue lesions)(20). The morphology of red and white implant types can have a wide variation, and may be difficult to distinguish from healthy peritoneum (21). A systematic review on the accuracy of laparoscopy (22) to diagnose endometriosis showed that, when looking at the value of the visual diagnosis of endometriosis at laparoscopy, only a limited amount of reports of good quality exist (N=4). The accuracy of a diagnostic laparoscopy for endometriosis was evaluated in 433 patients. A negative diagnostic laparoscopy (i.e. a laparoscopy during which no endometriosis is identified) was shown to be highly accurate for excluding endometriosis and therefore useful to the clinician in terms of decision-making. However, a positive laparoscopy (i.e. a laparoscopy during which endometriosis is identified) is less informative and of limited value when used in isolation.

The need for better visualization led to a rise in the amount of studies in which different types of contrast agents were used. Intraoperative staining has been used in medicine as a safe and effective method to assess anatomy, physiology and pathology (23).

Endometriosis may be easier to distinguish from normal tissue through the use of so-called enhanced imaging using contrast agents during surgery.

5-ALA has been used in a broad spectrum of treatments in urology, dermatology, gastroenterology, neurosurgery and gynecology (24, 25). 5-ALA is a precursor of Protoporphyrin IX that has a strong photosensitizing activity. It is pre-operatively administered as an oral solution, dissolved in mineral water or juice. The dose is calculated as a fixed amount of dye per kilogram bodyweight varying between 1 – 30 milligrams per kg (26-29). Due to reported photo toxicity, intraoperative care such as filtering the operating theatre lights and covering the skin and postoperative care such as maintenance of the patient in subdued light for 48 hours after ingestion, should be taken.

Methylene blue (MB) has been widely applied in gynecology for e.g. assessing the tubal patency, for visualization of sentinel nodes in breast cancer surgery but also for ureteral visualization in urology (30-32). For the latter indication the dye is used in combination with near-infrared fluorescence imaging. It is reported that this water-based dye has a higher affinity to attach to the endometrial tissue than peritoneal tissue due to the high fat concentrations of the latter (33).

Indigo Carmine has, amongst others, been used in urology for localizing ureteral orifices during cystoscopy and ureteral catheterization. In obstetric surgery, indigo carmine solutions are sometimes employed to detect amniotic leaks (34, 35).

Indocyanine Green (ICG) has been used in medicine since the late 1950s to measure cardiac output, liver function and to study anatomy of the retinal vessels. ICG was approved by the FDA as a contrast agent in 1959 and has been widely applied ever since. (36) Near-infrared fluorescence imaging with ICG has been used in gynecology for e.g. sentinel lymph node mapping in patients with endometrial cancer. (37)

Bloody peritoneal fluid during surgery may be a result of retrograde menstruation, intraperitoneal bleeding or laparoscopic trocar insertion. This bloody fluid has been used as “a contrast dye” to paint the peritoneal surfaces in an attempt to visualize peritoneal endometriosis. The erythrocytes stream around the subtle deformities of the peritoneum, thus outlining the abnormal areas that may represent endometriosis.

The aim of this review is to provide an overview of the literature on the intraoperative laparoscopic visual enhancement of peritoneal endometriosis using contrast agents.

METHODS

Literature Search Strategy

A systematic literature search was conducted until 01.12.2016 by 2 authors (MA, SH) independently. There were no restrictions on study design, population characteristics or language. All titles and abstracts emanating from the search were screened and assessed for eligibility. Furthermore, the references of the selected literature were reviewed for additional articles. Any differences in the search were discussed between the 2 authors, and consensus was reached following discussion. If no consensus was reached, a third author (LS) decided.

Data extraction

The extraction of data (including general study information, study characteristics, design, interventions, outcomes and results) from the selected studies was performed by 2 authors independently (MA, SH).

Information sources

The database search included the PubMed database, the Embase database and the Cochrane Library. Other tools that were used to find relevant sources include trial registries (<http://www.controlled-trials.com/>, <https://www.clinicaltrials.gov/>, <https://www.clinicaltrialsregister.eu/>, <https://www.toetsingonline.nl/>, <http://www.trialregister.nl>) and Google Scholar.

Inclusion Criteria

To be included, studies had to meet the following criteria: (1) description of laparoscopic endometriosis imaging with a contrast agent; (2) report of visual findings of endometriosis during laparoscopy.

Exclusion Criteria

The following studies were excluded: (1) studies that did not meet the inclusion criteria; (2) studies conducting research other than on human subjects; (3) Letters and comments on articles.

RESULTS

A total of 144 records was identified through database searching. The search strategy is described in appendix 1. After the removal of duplicates, a total of 130 records was screened of which 112 records were excluded by abstract review. The remaining full text articles were assessed for eligibility of which 12 articles were excluded. 3 additional records were found after scanning the reference list of the included records. Finally, for this review, a total of 9 studies, concerning a combined total of 171 patients, was included. Figure 1 shows the flow chart of study selection with reasons for exclusion.

Contrast agents

The general characteristics of the included studies are summarized in table I. Five agents are described for enhanced visualization of endometriosis: 4 articles discuss 5-ALA, 2 MB, 1 case report discusses indigo carmine, 1 case looks at bloody peritoneal fluid and 1 case discusses ICG respectively.

The methods and materials used to administer the different dyes are outlined in table II. Dosing was not uniform and was not always specified.

The terminology for describing the endometriosis lesions was not uniformly according to the revised American Society of Reproductive Medicine classification. The description in the different studies is given in table III.

In table IV the main results and conclusions per study are outlined.

In the next section, details about (results of) the use of the 5 dyes are provided, grouped per dye.

5-ALA

Malik et al. (29) studied a total of 16 patients, 6 of whom received topical 5-ALA and 10 of whom received oral 5-ALA.

They found that, while both the topical and oral application detected all red and white endometriosis lesions, they did not detect any of the brown/black lesions.

Topical application of 5-ALA proved to be associated with a high rate of photo toxicity such as facial erythema. And one of the patients presenting with this suffered from edema and blistering. The symptoms appeared after short exposure to light 8 to 24 hours after 5-ALA was applied. According to the authors, these side effects were serious and intolerable. No complications were encountered in the patients who received 5-ALA orally.

In a further study by the same group (28), 37 patients were orally given 30mg/kg of 5-ALA. The detection of endometriosis was 100% on sensitivity and 75% on specificity. In this study, 2 cases of facial erythema occurred during the first 24 hours after 5-ALA was applied, as a result of patients' noncompliance with sunlight exposure restrictions. The authors of the study concluded that using 5-ALA can improve the diagnosis of endometriosis in non-pigmented and occult endometrial lesions.

In another study, Buchweitz et al. (26) studied the results of using 20mg/kg of orally administered 5-ALA in diagnosing non-pigmented (red and white) endometriosis lesions. They looked at cases in which 5-ALA was given between 5 and 7 hours before surgery, and at cases in which it was administered 10 to 14 hours before surgery. 24 consecutive patients with suspected endometriosis undergoing laparoscopy were included in either of the two groups. In this study, the sensitivity and specificity of the detection of endometriosis lesions was not different between the two timings of administration (with sensitivity at 91% vs 92%, and specificity at 79% vs 78%). Overall, the use of 5-ALA in the diagnosis of endometriosis lesions yielded an improvement of 35% as compared to using white light illumination. In addition, the sensitivity, using a dosage of 20 mg/kg was found to be similar to the sensitivity achieved with a 30 mg/kg dose, as has been established in previous studies. Despite the precautions Buchweitz et al put in place, 2 cases of nausea occurred after the application of 5-ALA. The diagnosis was histologically confirmed.

Hillemans et al. (27) conducted a study in which fifteen patients were included. Patients received either 1mg/kg or 10mg/kg of 5-ALA, between 1.5 and 6 hours before surgery. In both cases the 5-ALA was given orally. The administration of 5-ALA in a concentration of 1mg/kg proved to be too low for diagnosing endometriosis lesions through fluorescence imaging. In the patients that received 5-ALA in a concentration of 10mg/kg, 100% of the non-pigmented red lesions showed fluorescence and 60% of the non-pigmented white lesions showed fluorescence. However, none of the pigmented black lesions showed fluorescence. The diagnosis was confirmed histologically. The authors concluded that using 5-ALA orally, in a dose of 10mg/kg, 3 to 6 hours before surgery, may be beneficial in the diagnosis of active peritoneal endometriosis.

In conclusion, 5-ALA enabled the detection of red and white lesions, but not the detection of pigmented lesions, if it is administered orally in a dosage of 10-30 mg/kg. Furthermore, administering the 5-ALA between 1.5 and 24 hours before surgery seems adequate, with evidence that a dose of 10-20 mg/kg would be sufficient.

METHYLENE BLUE

Lessey et al. (38) included 45 patients in their study and sprayed concentrated MB (1:200 dilution in sterile saline) onto their pelvic surfaces using an aspiration needle, and then rinsed with lactated Ringer's solution. The purpose of the study was to demonstrate the use of methylene blue to stain peritoneal surfaces during laparoscopy in order to detect the loss of peritoneal integrity in patients with pelvic pain and suspected endometriosis. Areas of localized dye uptake were evaluated for the presence of endometriosis lesions. These areas were resected and fixed in 2.5% buffered glutaraldehyde and examined by scanning electron microscopy (SEM).

Intense peritoneal MB uptake was associated with endometriosis in 85% (34/40) of patients with Chronic Pelvic Pain (CPP). In 2/5 of the patients without CPP localized dye uptake was seen, but no resection of these lesions was performed. Pain relief after resection of MB stained areas was reported in 80% (32/40) of patients with CPP. Based on SEM, the authors concluded that endometrial cells extend well beyond visible implants of endometriosis and appear to disrupt the underlying mesothelium. The authors hypothesized that subtle lesions of endometriosis could therefore cause pelvic pain that is secondary to disruption of epithelial surfaces and the underlying mesothelium. This allows blood and inflammatory factors to reach the underlying sensory nerves. In case of normal peritoneum without blue dye staining, the cells are tightly connected. Overall, this study showed that staining with MB improves the detection of subtle and nearly invisible endometriosis lesions. This improved detection may serve to elevate the accuracy of laparoscopies done to diagnose endometriosis.

In the study of Manhes et al. (33) 31 patients were included in which intraoperative MB staining was performed. More specifically, a 5 ml dilute of MB was dispersed over the pelvic peritoneal surface, then washed with a physiologic saline solution until clear fluid was aspirated. Extensive areas of dark blue discoloration were observed. The persistent discolored peritoneal areas were believed to be suggestive for endometriosis and were eliminated by bipolar coagulation or CO₂ laser. However, in this study no biopsies for histologic confirmation of endometriosis were taken.

These results suggest that endometriosis staining with MB is feasible due to the hypothesized higher uptake of MB on peritoneal surface irregularities caused by endometriosis.

OTHER DYES (INDIGO CARMINE, ICG, BLOOD)

Rauh-Hain et al. (39) reported a case of a 29-year-old nulligravid woman with a history of endometriosis and left unicornuate uterus with an indication for surgical removal of the endometriosis lesions. Laparoscopy and

chromopertubation with indigo carmine was performed. It was shown that the diagnosis of endometriosis was made by visual detection of red and white lesions. Indigo carmine blue dye that spilled from the left fallopian tube stained the areas in close proximity to the fallopian tubes, after transcervical application of indigo carmine showing endometriosis lesions. These were already appreciated in conventional laparoscopy. No biopsies were taken in this study to confirm the diagnosis histologically, and no extra precautions were specified concerning the (use of) contrast agents or (the occurrence of) adverse reactions.

In a case report by Levey et al. (40) a 32-year-old female patient with CPP received a 5 mg bolus of ICG intravenously during laparoscopy with the robotic DaVinci Si System with built-in fluorescence detection technology highlighting visible areas of endometriosis in conventional laparoscopy mode which subsequently appeared strongly green in fluorescence mode. This illumination occurred approximately 60 seconds after the dye was administered. Moreover, there was an area that appeared normal in conventional mode and green in fluorescence mode only. This lesion was resected and the biopsies confirmed the presence of endometriosis. No adverse reactions and no precautions related to the contrast agent were taken. The authors concluded that using the daVinci SI platform in combination with ICG has the potential to offer a greater intraoperative ability to detect endometriosis lesions and improve its surgical management.

Redwine et al. (41) reported that painting the peritoneal surfaces with bloody peritoneal fluid resulted in highlighted irregularities by observing the erythrocytes that stream around them. After rinsing off the bloody fluid, it was possible to recognize these lesions. One lesion that was not readily visible in white light imaging was detected in this way. Once it was excised, histologic evaluation showed the presence of endometrial glands and stroma. The authors concluded that painting with bloody peritoneal fluid can assist the surgeon in the identification of subtle endometriosis. No complications were encountered in this study.

COMMENT

This study presents an overview of intraoperative enhanced imaging of endometriosis lesions.

Since destruction of peritoneal endometriosis is effective in treating pain symptoms experienced by women with subfertility and women in general, improving the recognition of peritoneal endometriosis could lead to improved efficacy of treatment. Therefore, the final goal of enhanced intraoperative imaging of peritoneal disease is a more radical destruction of all peritoneal lesions resulting in less pain and more pregnancies. Moreover, the recurrence rate of symptomatic disease should be lower as well. Postoperative recurrence of symptoms and histologically proven endometriosis is more likely to cluster close to the original area of involvement, reflecting either incomplete resection at the initial surgery or a nonrandom favored implantation of new endometrial implants in adjacent peritoneum (15, 16, 42, 43).

Several dyes and staining techniques have been investigated to help surgeons find and surgically destroy lesions of peritoneal endometriosis during laparoscopy. Of the 5 contrast agents mentioned in this review, the contrast agent 5-ALA has been evaluated most extensively. Several studies have shown that the use of 5-ALA is feasible and may be beneficial in the diagnosis of active peritoneal endometriosis, with reported sensitivity rates of up to 100% and reported specificity rates of up to 78%. 5-ALA is predominantly administered orally. The contrast agent allowed for the detection of red and white lesions, but didn't aid the detection of non-pigmented lesions. Studies have shown an oral dose of 10-30 mg/kg allows imaging to be obtained. Furthermore, administering 5-ALA between 1,5 and 24 hours before surgery seems adequate, with evidence that a dose of 10-20 mg/kg would be sufficient.

However, although promising, the use of 5-ALA may be problematic as it harbors side effects of photosensitivity and cytotoxicity, and therefore requires precautions such as avoiding sunlight for 24-48 hours after administration. Despite these precautions, 5 patients developed adverse reactions because they didn't comply with the precautions. In contrast with the other contrast agents this review focusses on, 5-ALA is not administered intraoperatively, but 1,5 to 24 hours prior to surgery.

Methylene Blue (MB) was shown, in 2 studies, to have potential in identifying peritoneal endometriosis in up to 85% of suspected endometriosis lesions after staining the peritoneum with MB. This may serve to elevate the accuracy of diagnosing endometriosis during laparoscopy. No adverse reactions related to the use of MB were specified or encountered in these 2 studies.

The use of Indigo Carmine was reported in one case, in which transcervical application of this contrast agent resulting in staining with Indigo Carmine being seen in close proximity to endometriosis lesions. However, as this occurrence was only seen in one case, it is unknown what the reproducibility of this technique is. Moreover, as staining was achieved due to dye that spilled from the fallopian tube, this technique might not be suitable for assessing lesions at a further distance from the tube, or when there is a lack of patency of the tubes.

Another technique which may help identify endometriosis is staining of the peritoneum with bloody peritoneal fluid.

However, it should be noted that all traumatized areas with surface irregularities are stained regardless of the cause of the

trauma. Therefore, the clinical relevance and reproducibility of this technique in the diagnosis and treatment of endometriosis is not clear.

Near-infrared fluorescence imaging with perioperative ICG administration is a novel technique for enhanced intraoperative visualization. The fact that this technique can highlight hyper- and hypovascularized tissue, has led to its regular use in displaying vascular anatomy and perfusion (44). This characteristic of the technique also makes it promising in diagnostic laparoscopy for endometriosis (40). The case report by Levey illustrates this potential.

The present review is hindered by several shortcomings.

In two of the reviewed studies no histologic confirmation of the diagnosis was done. In other words: the authors relied solely on the visual characteristics of the lesions (33, 39), which puts the certainty of the diagnosis into question.

Due to the small number of subjects included in most studies, it was not possible to report on the sensitivity or specificity of the technique.

Furthermore, despite the clear categorization of the various types of endometriosis as proposed by the American Society of Reproductive Medicine (20), the studies that were reviewed are inconsistent in their nomenclature. If authors would use a more uniform description of the lesions and, more specifically, adhered to the nomenclature proposed by the ASRM, this would enable better comparability between the various studies. Incorporation of composite endpoints, such as has been proposed in liver surgery, is also needed for endometriosis studies.(45).

The optimal dye for intraoperative visualization of endometriosis has not been identified yet. 5-ALA shows good results but has the disadvantage of photosensitivity and of the interval between administration and fluorescence.

Based on its easy clinical application with few side effects, near-infrared fluorescence imaging using ICG might be promising, as has been established in other fields of laparoscopic surgery (36, 46). Further studies will have to establish its exact value.

Targeted fluorescent imaging might also play a role. In this technique, fluorophores are coupled to specific antibodies and targeted at compounds of tissue of interest, a technique which has been proven to work in breast cancer(47).

We hypothesize that fluorescence imaging is at present the most promising technique and advocate further investigation for improved detection of endometriosis.

Conclusion

Limited data is available on perioperative laparoscopic enhanced imaging of endometriosis lesions. Although the reviewed studies, which were aimed at elevating the success rate of methods to detect endometriosis, offer promising results, further investigation is required into the clinical applicability, reproducibility and significance of the studies, before solid conclusions can be drawn. Therefore, based on the present data no technique of preference can be identified. Further research into the optimal technique is required.

Acknowledgements

N/A

Funding

No funding was required for this systematic review.

Conflict of interest

None of the authors have any conflicts of interest to declare

Appendix 1 Search 01.12.2016

(((((Methylene blue) OR blue dye) OR Indocyanine green) OR ICG) OR green dye) OR 5-ALA) OR 5-aminolevulinic acid) OR fluorophore) OR porphyrin fluorescence) OR fluorescent dye) OR fluorescent) OR fluorescence) OR fluorescence imaging) OR coloring dye) OR coloring agent) OR contrast agent) OR contrast dye) OR dye) OR stain) OR staining) OR stained tissue))

AND (((((((laparoscopy) OR laparoscopic) OR laparoscopic surgery) OR robot) OR robot assisted) OR robot assisted surgery) OR robotic) OR robotic surgery) OR da vinci) OR daVinci) OR da vinci robot) OR da vinci robotic) OR da vinci surgery) OR minimally invasive) OR minimally invasive surgery))

AND (((((endometriosis) OR peritoneal endometriosis) OR endometriotic) OR endometriotic lesions) OR endometrial) OR endometrial lesions))

AND (((((((fluorescence imaging) OR near infrared) OR near-infrared) OR NIR) OR near infrared imaging) OR near-infrared imaging) OR near infrared fluorescence imaging) OR near-infrared fluorescence imaging) OR NIRF imaging) OR enhanced imaging) OR imaging) OR fluorescence diagnosis) OR photodynamic diagnosis) OR diagnostic accuracy))

AND (((((((Methylene Blue [Mesh]) OR Indocyanine Green [Mesh]) OR Aminolevulinic Acid [Mesh]) OR Fluorescent Dyes [Mesh]) OR Coloring Agents [Mesh]) OR Contrast Media [Mesh]) OR Luminescent Agents [Mesh]) OR Staining and Labeling [Mesh]) OR Laparoscopy [Mesh]) OR Robotic Surgical Procedures [Mesh]) OR Minimally Invasive Surgical Procedures [Mesh]) OR Endometriosis [Mesh])

Scholar.google.com:

"endometriosis" AND "laparoscopy" AND "fluorescence imaging" -fallopian -hysterosalpingography -HSG -MRI -"MR imaging" -"sentinel node" -"sentinel lymph node" -"dye-test"

References

1. Barcena de Arellano ML, Mechsner S. The peritoneum--an important factor for pathogenesis and pain generation in endometriosis. *J Mol Med (Berl)*. 2014;92(6):595-602.
2. Kennedy S, Bergqvist A, Chapron C, D'Hooghe T, Dunselman G, Greb R, et al. ESHRE guideline for the diagnosis and treatment of endometriosis. *Hum Reprod*. 2005;20(10):2698-704.
3. Kodaman PH. Current strategies for endometriosis management. *Obstet Gynecol Clin North Am*. 2015;42(1):87-101.
4. Hey-Cunningham AJ, Peters KM, Zevallos HB, Berbic M, Markham R, Fraser IS. Angiogenesis, lymphangiogenesis and neurogenesis in endometriosis. *Front Biosci (Elite Ed)*. 2013;5:1033-56.
5. Andres Mde P, Podgaec S, Carreiro KB, Baracat EC. Endometriosis is an important cause of pelvic pain in adolescence. *Rev Assoc Med Bras*. 2014;60(6):560-4.
6. Kvaskoff M, Mu F, Terry KL, Harris HR, Poole EM, Farland L, et al. Endometriosis: a high-risk population for major chronic diseases? *Hum Reprod Update*, 21(4) (2015), 500-516.
7. Klein S, D'Hooghe T, Meuleman C, Dirksen C, Dunselman G, Simoens S. What is the societal burden of endometriosis-associated symptoms? a prospective Belgian study. *Reprod Biomed Online*. 2014;28(1):116-24.
8. De Graaff AA, D'Hooghe TM, Dunselman GA, Dirksen CD, Hummelshoj L, Consortium WE, et al. The significant effect of endometriosis on physical, mental and social wellbeing: results from an international cross-sectional survey. *Hum Reprod*. 2013;28(10):2677-85.
9. Abbott JA, Hawe J, Clayton RD, Garry R. The effects and effectiveness of laparoscopic excision of endometriosis: a prospective study with 2-5 year follow-up. *Hum Reprod*. 2003;18(9):1922-7.
10. Friedl F, Riedl D, Fessler S, Wildt L, Walter M, Richter R, et al. Impact of endometriosis on quality of life, anxiety, and depression: an Austrian perspective. *Arch Gynecol Obstet*. 2015; 292(6):1393-9
11. Moawad NS, Caplin A. Diagnosis, management, and long-term outcomes of rectovaginal endometriosis. *Int J Womens Health*. 2013;5:753-63.
12. Dunselman GA, Vermeulen N, Becker C, Calhaz-Jorge C, D'Hooghe T, De Bie B, et al. ESHRE guideline: management of women with endometriosis. *Hum Reprod*. 2014;29(3):400-12.
13. Slabuszewska-Jozwiak A, Ciebiera M, Baran A, Jakiel G. Effectiveness of laparoscopic surgeries in treating infertility related to endometriosis. *Ann Agric Environ Med*. 2015;22(2):329-31.
14. Jacobson TZ, Duffy JM, Barlow D, Koninckx PR, Garry R. Laparoscopic surgery for pelvic pain associated with endometriosis. *Cochrane Database Syst Rev*. 2009(4):CD001300.
15. Taylor E, Williams C. Surgical treatment of endometriosis: location and patterns of disease at reoperation. *Fertility and sterility*. 2010;93(1):57-61.
16. Vignali M, Bianchi S, Candiani M, Spadaccini G, Oggioni G, Busacca M. Surgical treatment of deep endometriosis and risk of recurrence. *Journal of minimally invasive gynecology*. 2005;12(6):508-13.
17. Stegmann BJ, Sinaii N, Liu S, Segars J, Merino M, Nieman LK, et al. Using location, color, size, and depth to characterize and identify endometriosis lesions in a cohort of 133 women. *Fertil Steril*. 2008;89(6):1632-6.
18. Laufer MR. Identification of clear vesicular lesions of atypical endometriosis: a new technique. *Fertil Steril*. 1997;68(4):739-40.

19. Overton C DC, McMillan L, Shaw RW, Koh C. Atlas of Endometriosis. 3rd ed: Informa Medical; 2007. 116 p.
20. Revised American Society for Reproductive Medicine classification of endometriosis: 1996. *Fertil Steril*. 1997;67(5):817-21.
21. Jansen RP, Russell P. Nonpigmented endometriosis: clinical, laparoscopic, and pathologic definition. *Am J Obstet Gynecol*. 1986;155(6):1154-9.
22. Wykes CB, Clark TJ, Khan KS. Accuracy of laparoscopy in the diagnosis of endometriosis: a systematic quantitative review. *BJOG*. 2004;111(11):1204-12.
23. Roberts HW, Donati-Bourne JF, Wilson VL, Wilton JC. The use of live fluorescence staining techniques in surgery: a review. *Journal of investigative surgery : the official journal of the Academy of Surgical Research*. 2013;26(5):283-93.
24. Loning M, Diddens H, Friedrich M, Altgassen C, Diedrich K, Huttman G. [Fluorescence diagnosis and photodynamic therapy with 5-aminolevulinic acid induced protoporphyrin IX in gynecology: an overview]. *Zentralbl Gynakol*. 2006;128(6):311-7.
25. Soergel P, Rinnau F, Hillemanns P. Fluoreszenzdiagnostik mit 5-Aminolävulinsäure-induziertem Protoporphyrin IX in der Gynäkologie. *Gynäkologe*. 2007;40(5):338-42.
26. Buchweitz O, Wulfig P, Staebler A, Kiesel L. Detection of nonpigmented endometriotic lesions with 5-aminolevulinic acid-induced fluorescence. *J Am Assoc Gynecol Laparosc*. 2004;11(4):505-10.
27. Hillemanns P, Weingandt H, Stepp H, Baumgartner R, Xiang W, Korell M. Assessment of 5-aminolevulinic acid-induced porphyrin fluorescence in patients with peritoneal endometriosis. *American journal of obstetrics and gynecology*. 2000;183(1):52-7.
28. Malik E, Berg C, Meyhofer-Malik A, Buchweitz O, Moubayed P, Diedrich K. Fluorescence diagnosis of endometriosis using 5-aminolevulinic acid. *Surg Endosc*. 2000;14(5):452-5.
29. Malik E, Meyhöfer-Malik A, Trutenau D, Diddens H, Küpker W, Diedrich K. Pilotstudie zur photodynamischen Diagnostik der Endometriose mittels 5-Aminolävulinsäure. *Geburtshilfe Frauenheilkd*. 1998;58(08):420-5.
30. Ansari AH. Methylene blue test for assessment of tubal patency: a new and simple technique. *Can Med Assoc J*. 1968;99(4):182-4.
31. Simmons R, Thevarajah S, Brennan MB, Christos P, Osborne M. Methylene blue dye as an alternative to isosulfan blue dye for sentinel lymph node localization. *Ann Surg Oncol*. 2003;10(3):242-7.
32. Al-Taher M, van den Bos J, Schols RM, Bouvy ND, Stassen LP. Fluorescence Ureteral Visualization in Human Laparoscopic Colorectal Surgery Using Methylene Blue. *J Laparoendosc Adv Surg Tech A*. 2016;26(11):870-5.
33. Manhes H, Shulman A, Haag T, Canis M, Demontmarin JL. Infertility due to diseased pelvic peritoneum: laparoscopic treatment. *Gynecologic and obstetric investigation*. 1994;37(3):191-5.
34. Song JE, Kim SK. The use of indigo carmine in ureteral operations. *J Urol*. 1967;98(6):669-70.
35. Beckmann MW, Wiegratz I, Dereser MM, Baier P, Born HJ. [Diagnosis of rupture of fetal membranes: comparison of vaginal detection of fetal fibronectin and intra-amnion injection of indigo carmine]. *Geburtshilfe Frauenheilkd*. 1993;53(2):86-91.
36. Boni L, David G, Mangano A, Dionigi G, Rausei S, Spampatti S, et al. Clinical applications of indocyanine green (ICG) enhanced fluorescence in laparoscopic surgery. *Surg Endosc*. 2015;29(7):2046-55.
37. Rossi EC, Jackson A, Ivanova A, Boggess JF. Detection of sentinel nodes for endometrial cancer with robotic assisted fluorescence imaging: cervical versus hysteroscopic injection. *Int J Gynecol Cancer*. 2013;23(9):1704-11.
38. Lessey BA, Higdon HL, 3rd, Miller SE, Price TA. Intraoperative detection of subtle endometriosis: a novel paradigm for detection and treatment of pelvic pain associated with the loss of peritoneal integrity. *Journal of visualized experiments : JoVE*. 2012;70:4313
39. Rauh-Hain JA, Laufer MR. Increased diagnostic accuracy of laparoscopy in endometriosis using indigo carmine: a new technique. *Fertil Steril*. 2011;95(3):1113-4.

40. Levey KA. Use of fluorescence imaging technology to identify peritoneal endometriosis: a case report of new technology. *Surgical laparoscopy, endoscopy & percutaneous techniques*. 2014;24(2):e63-5.
41. Redwine DB. Peritoneal blood painting: an aid in the diagnosis of endometriosis. *Am J Obstet Gynecol*. 1989;161(4):865-6.
42. Sibiude J, Santulli P, Marcellin L, Borghese B, Dousset B, Chapron C. Association of history of surgery for endometriosis with severity of deeply infiltrating endometriosis. *Obstetrics and gynecology*. 2014;124(4):709-17.
43. Vercellini P, Crosignani PG, Abbiati A, Somigliana E, Vigano P, Fedele L. The effect of surgery for symptomatic endometriosis: the other side of the story. *Human reproduction update*. 2009;15(2):177-88.
44. Namikawa T, Sato T, Hanazaki K. Recent advances in near-infrared fluorescence-guided imaging surgery using indocyanine green. *Surg Today*. 2015;45(12):1467-74.
45. de Meijer VE. Development of a composite endpoint for randomized controlled trials in liver surgery (*Br J Surg* 2011; 98: 1138-1145). *Br J Surg*. 2011;98(8):1145-6.
46. Schols RM, Lodewick TM, Bouvy ND, van Dam DA, Meijerink WJ, van Dam GM, et al. Near-infrared fluorescence laparoscopy of the cystic duct and artery in pigs: performance of a preclinical dye. *J Laparoendosc Adv Surg Tech A*. 2014;24(5):318-22.
47. Lamberts LE, Koch M, de Jong JS, Adams A, Glatz J, Kranendonk ME, et al. Tumor-specific uptake of fluorescent bevacizumab-IRDye800CW microdosing in patients with primary breast cancer: a phase I feasibility study. *Clin Cancer Res*. 2017;23(11):2730-41.

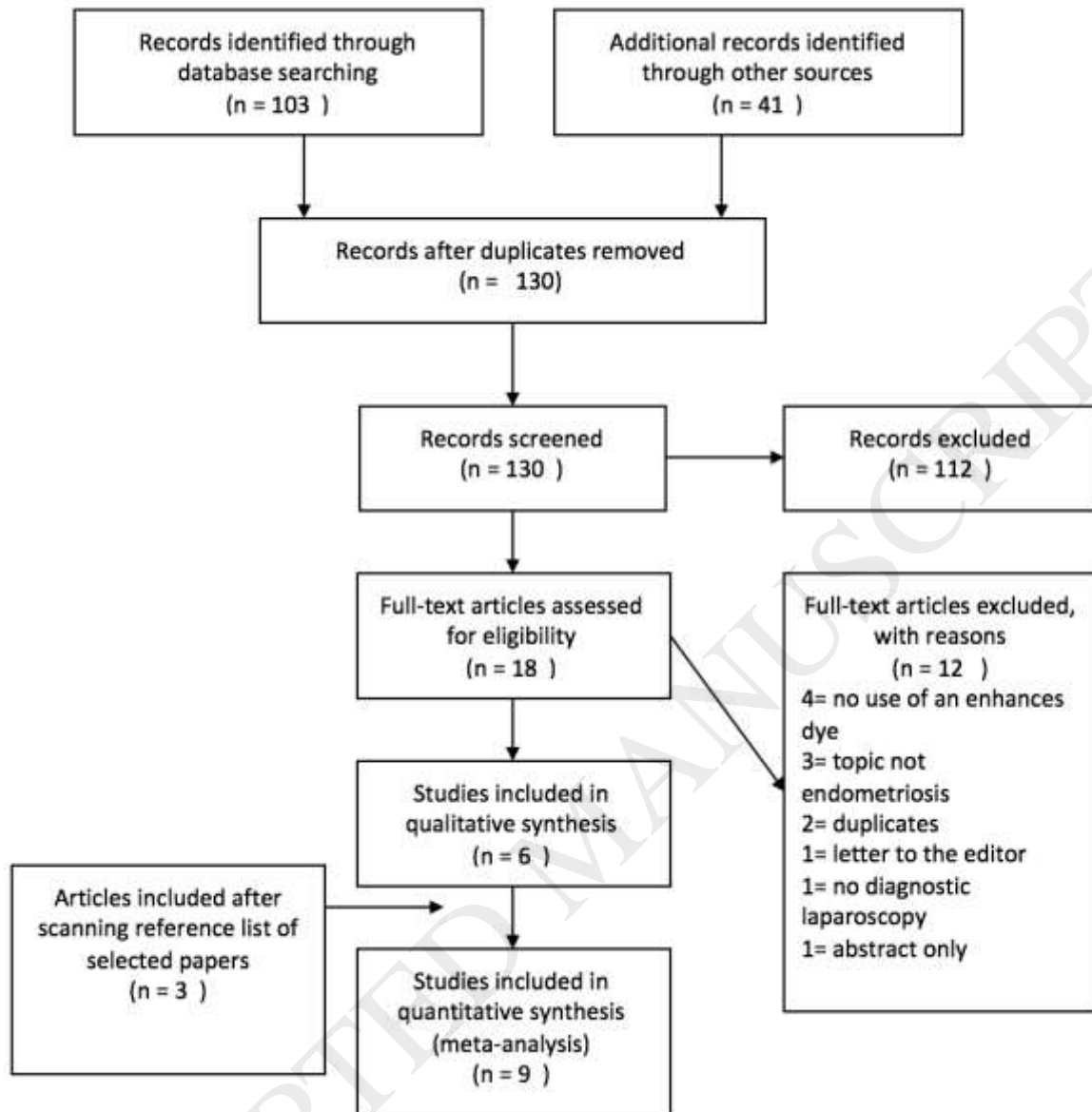


Figure 1. Flow diagram of literature search and study selection.

Table 1 Characteristics of included studies

Study	Country	Year	System	n	Contrast Agent
Buchweitz et al. (26)	Germany	2004	Karl Storz, D-light System	24	5-ALA
Hillemans et al.(27)	Germany	2000	Karl Storz D-light system	15	5-ALA
Malik et al. (29) Pilot study	Germany	1998	Karl Storz, D-light system	16	5-ALA
Malik et al. (28)	Germany	2000	Karl Storz, D-light system	37	5-ALA
Lessey et al(38)	USA	2012	NS	45	MB
Manhes et al(33)	France	1994	NS	31	MB
Rauh-Hain et al. (39)	USA	2011	NS	1	Indigo Carmine
Levey et al.(40)	USA	2014	DaVinci Si	1	ICG
Redwine et al. (41)	USA	1989	NS	-	Bloody peritoneal fluid

5-ALA 5-aminolevulinic acid, ICG Indocyanine Green, MB Methylene Blue, NS Not specified

Table 2 Methods and materials for administration of the dyes

Study	Contrast Agent	Dosage	Time of application	n	Method of administration	Precautions
Buchweitz et al. (26)	5-ALA	20 mg/kg	5-7 and 10-14 h before surgery	24	Orally, dissolved in apple juice	-Avoiding of sunlight for 24 hours after 5-ALA application
Hillemans et al. (27)	5-ALA	1 mg/kg (n=5) 10 mg/kg (n=10)	1,5-6 h before surgery	15	Orally, dissolved in mineral water.	- Avoiding of intense light for 24 hours after surgery - Routine biochemical testing and total blood count before and 1 day after 5-ALA application - Monitoring for local and systemic toxicity 1 and 3 days after fluorescence imaging
Malik et al. (29)	5-ALA	Topical (n=6) : 100 ml 3% ALA-solution Orally (n=10): 15-30 mg/kg	Topical: 4-12 h before surgery Orally: 4-11 h before surgery	16	Topical, trans uterine application through a catheter Orally, dissolved in 50ml apple juice	- Avoiding of direct sunlight for 48 hours after 5-ALA application and staying in a darkened room - Smearing sunblock on light-exposed parts of the body for 48 hours after 5-ALA application
Malik et al. (28)	5-ALA	30 mg/kg	10-14 h before surgery	37	Orally, dissolved in 50ml apple juice	- Avoiding of sunlight for 48 hours after 5-ALA application and preferably staying indoors - Covering all skin areas directly exposed to sunlight with sun blocker - Wearing sunglasses
lessey et al. (38)	MB	MB 1:200 mix with sterile saline	Intraoperative	45	Injected onto pelvic surfaces using an aspiration needle, then rinsed with Lactated Ringers solution	NS
Manhes et al. (33)	MB	5 ml dilute MB solution	Intraoperative	31	"MB painting test"; dispersing of MB over the pelvic peritoneal surface with a "spray-like" effect, then washed with a physiologic saline solution until clear fluid was aspirated	NS
Rauh-Hain et al. (39)	Indigo Carmine	Unspecified	Intraoperative	1	Chromopertubation: blue dye that spilled from the left fallopian tube stained the endometriosis lesions	NS
Levey et al. (40)	ICG	5 mg bolus	Intraoperative	1	Intravenous	NS
Redwine et al. (41)	Bloody peritoneal fluid	Unspecified	intraoperative	NS	Painting of the bloody peritoneal fluid (intraoperatively encountered) onto the peritoneal surfaces	NS

5-ALA 5-aminolevulinic acid, MB Methylene blue, ICG Indocyanine Green, NS Not specified

*Routine biochemical examination consists of sodium, potassium, creatinine and aspartate aminotransferase

Table 3 Terminology for the different types of endometriosis

Study	Not-highlighting		Highlighting
Buchweitz et al. (26)	Pigmented "black" / not active	Vs	Subtle / occult / nonpigmented "red" and "white" / active
Hillemans et al.(27)	Clearly visible/ nodular/ pigmented/ cysts	Vs	Hardly detectable "petechial" and "hemorrhagic" / active "red" and "white"
Malik et al. (29)	Typical darkish / non-active	vs	Atypical / active / proliferating
Malik et al. (28)	Pigmented "powder burn" / inactive	vs	Occult / proliferating and highly active / nonpigmented "small vesicles", "nodular lesions", "plaque-type implants"
lessey et al. (38)	Visible	vs	Subtle / very subtle / invisible / subclinical / single cell layer / surface red lesions
Manhes et al.(33)	Subclinical	Vs	Subtle
Rauh-Hain et al.(39)	Not mentioned	Vs	Subtle/ clear and red-and-white/ nonpigmented "small vesicles", "nodular lesions", "plaque-type implants"
Levey et al. (40)	Avascular / black lesion / black implant / white scar	vs	Vascular
Redwine et al. (41)	Not mentioned	vs	Subtle / colorless

vs versus

Table 4 Results and conclusion

Study	Method of taking biopsies	Histologic confirmation	Results	Side effects	Conclusion
Buchweitz et al. (26)	107 biopsies taken from: - all suspicious areas - fluorescent lesions - unaffected areas as internal control	Yes; For each specimen, three step sections were examined. Histologic examination performed by one experienced pathologist. Diagnosis confirmed by the presence of glands and stroma.	Diagnosis in non-pigmented areas <u>10-14 h before surgery:</u> - White light ; 58% sensitivity, 64% specificity - Fluorescence; 92% sensitivity, 78% specificity <u>5-7 h before surgery:</u> - White light; 64% sensitivity, 67% specificity - Fluorescence; 91% sensitivity 79% specificity - 100% of non-pigmented red lesions shows fluorescence (n=18) - 60% of non-pigmented white lesions shows fluorescence (n=3) - 0% of pigmented black lesions shows fluorescence (n=0) - 0% of the control biopsies shows fluorescence (n=0)	2 cases of nausea after 5-ALA application.	Dosage of 20 mg/kg body weight of 5-ALA is appropriate for fluorescence diagnosis of nonpigmented endometriosis. Sensitivity similar between application 5-7 or 10-14 hours preoperatively. Sensitivity with 20 mg/kg similar to that achieved with 30 mg/kg dose.

Hillemans et al. (27)	Fluorescence-directed Biopsies taken from areas corresponding to the fluorescence and the white-light image	Yes; not specified	- White or red lesions show a better fluorescence signal than normal peritoneum. - 1 mg/kg 5-ALA too low for fluorescence imaging, 10mg/kg 3-6 hrs prior to surgery seemed adequate - Maximal fluorescence observed in the fimbrial mucosa	No side effects	Porphyrin fluorescence with 5-ALA may be beneficial in diagnosis of active peritoneal endometriosis. Phototoxic damage cannot be excluded at present, therefore caution to be taken due to the highest fluorescence in the fimbrial mucosa.
lessey et al. (38)	Areas with intense peritoneal staining resected and some examined with SEM	Yes; diagnosis carried out with SEM by visualization of endometrial cells and disruption in the cell-cell contacts of the underlying mesothelium. Photomicrographs obtained from 12 random areas.	Blue dye uptake in suspected lesions in women: - With CPP; 34/40 (85%) - Without CPP; 2/5 (40%) Improvement of pain relief after resection of blue stained areas in 32/40 (80%)	NS	Staining with MB appears to improve detection of subtle or nearly invisible endometriosis and may serve to elevate diagnostic accuracy for endometriosis at laparoscopy
Levey et al. (40)	Biopsy taken from areas that appeared abnormal with white light and areas that only appeared abnormal after administering ICG	Yes; diagnosis confirmed by the presence of glands and stroma.	Obvious areas of endometriosis appear strongly green after approximately 60 seconds. Biopsies revealed endometriosis.	No adverse reactions	Using the daVinci Si platform in combination with ICG has the potential to offer a greater intraoperative ability to detect endometriotic lesions and improve the surgical management of endometriosis.
Malik et al. (29) Pilot study	21 + 23 = 44 biopsies taken from visual suspected areas, from areas that show fluorescence and from areas that did not look suspicious as a negative control	Yes;	Fimbriae show high fluorescence in both application methods. Topical application: - 100% of red lesions shows fluorescence (n=1) - 100% of white lesions shows fluorescence (n=1) - 0 % of brown/black lesions shows fluorescence (n=0) - 100% of the control biopsies shows fluorescence (n=1) Oral application: - 100% of red lesions shows fluorescence (n=2) - 100% of white lesions shows fluorescence (n=2) - 0 % of brown/black lesions shows fluorescence (n=0) - 100% of the control biopsies shows fluorescence (n=1)	Topical application: - 3 cases of facial erythema of which 1 with edema and blistering due to patient compliance. Symptoms appeared after short exposure of light 8-24 after 5-ALA application and disappeared 5 days postoperative. Oral application: No complications	- Topical transuterine application of 5-ALA is associated with a high rate of serious phototoxicity that cannot be tolerated - The typical darkish endometriosis showed no fluorescence. - Photodynamic diagnosis of endometriosis using 5-ALA could improve the diagnosis of endometriosis
Malik et al. (28)	112 biopsies taken from visual suspected areas, from areas that are readily visible and show fluorescence, areas that only show fluorescence and from areas that did not look suspicious as a negative control	Yes; diagnosis confirmed by the presence of glandular epithelium and stroma.	Diagnosis in non-pigmented areas and normal-appearing peritoneum: - White light ; 69% sensitivity, 70% specificity - Fluorescence; 100% sensitivity, 75% specificity	2 cases of facial erythema during the first 24 h after ALA application due to patient behaviour regarding sunlight exposure. Complaints disappeared without sequelae 72 h after application.	Fluorescence diagnosis using 5-ALA feasible and can improve the diagnosis of endometriosis in nonpigmented and occult endometrial lesions.
Rauh-Hain et al. (39)	No biopsies taken	No;	Diagnosis made by visual detection of red-and-white lesions. Blue staining seen in close proximity to these areas after transcervically application of indigo carmine.	NS	Tissue staining with indigo carmine demonstrated lesions of endometriosis that were more easily identified and could therefore provide a more accurate diagnosis of endometriosis

Manhes et al.(33)	No biopsies taken	No;	after rinsing with a physiologic saline solution, the persistent pathologic peritoneal discolored areas were eliminated by bipolar coagulation or CO ₂ laser	No complications encountered	Staining with MB appears to improve procedure performance
-------------------	-------------------	-----	---	------------------------------	---

SEM Scanning Electron Microscopy, *CPP* Chronic Pelvic Pain, *NS* Not specified, *ICG* Indocyanine Green, *5-ALA* 5-aminolevulinic acid