



The prognostic significance of stage I ovarian clear cell and endometrioid carcinomas arising from endometriotic cysts: is it a myth?

Ali Ayhan¹ · Huseyin Akilli²  · Nihan Haberal³

Received: 30 January 2018 / Accepted: 3 July 2018 / Published online: 12 October 2018
© Springer-Verlag GmbH Germany, part of Springer Nature 2018

Abstract

Purpose The aim of this study was to determine the clinicopathologic features and the prognostic significance of Stage I ovarian clear cell and endometrioid carcinomas arising from endometriotic cysts.

Materials and methods Patients with either Stage I ovarian clear cell or endometrioid carcinoma were divided into three groups. *Group 1: Patients with cancers arising from endometriotic cysts *Group 2: Patients with ovarian and pelvic endometriosis *Group 3: Patients without endometriosis Patient characteristics (overall survival and disease-free survival) were compared between groups.

Results Of the 78 patients who participated in this study, 39 were in group 1, 13 were in group 2, and 26 were in group 3. The mean age in groups 1, 2, and 3 were 46 years, 54 years, and 48 years, respectively ($p=0.39$). Tumoral characteristics, including capsule rupture, positive cytology, grade, and the presence of synchronous endometrial cancer were similar in both groups. The 5-year overall survival rate in groups 1, 2, and 3 were 100, 90, and 93%, respectively ($p=0.4$). Moreover, the recurrence rates did not differ significantly between groups. Furthermore, subgroup analysis of clear cell carcinoma and endometrioid adenocarcinoma separately showed no effect of endometriosis on disease-free survival (DFS) or overall survival (OS).

Conclusion Clear cell or endometrioid ovarian carcinoma arising from ovarian and/or pelvic endometriosis shares the same clinicopathologic characteristics with their counterparts that do not arise from endometriosis and patients have similar overall and disease-free survival.

Keywords Endometriotic cyst · Stage I EOC · Prognosis · Gynecologic oncology

Introduction

Endometriotic cysts are cystic forms of ovarian endometriosis. They account for about 17–44% of all cases of endometriosis [1]. Endometriosis exhibits several features of invasive cancer and has been shown to undergo malignant transformations [2]. In addition to genetic studies, several clinical studies have reported such malignant

transformations, especially in endometrioid and clear cell cancer subtypes [3–6]. Recent researches indicate that patients with endometriosis have an increased lifetime risk of developing ovarian cancer [2, 7, 8]. Van Gorp et al. [9] reported an estimated prevalence between 0.9 and 4.5% for epithelial ovarian cancer (EOC) among patients with endometriosis.

As earlier studies were based on non-standardized patient selection criteria, they were unable to determine the prognostic significance of EOC originating from endometriosis [10–15]. EOC histology reports are very heterogeneous, making a comparison between various reports suboptimal. Additionally, the association between endometriosis and EOC survival outcomes remains unclear, as findings regarding this relationship have been inconsistent. Some studies observed that the survival rate was higher in patients with

✉ Huseyin Akilli
hsynakilli@hotmail.com

¹ Department of Gynecology and Obstetrics, Baskent University School of Medicine, Ankara, Turkey

² Baskent University School of Medicine, Ankara, Turkey

³ Department of Pathology, Baskent University School of Medicine, Ankara, Turkey

endometriosis than in non-endometriotic patients [14, 16]. However, others did not [11–13].

The relationship between endometriosis and EOC is not well-known. The molecular basis of the issue is a hot topic and recently, researchers have focused on it. Major genetic alterations have been reported, including PTEN, K-RAS, and β -catenin gene mutations, as well as loss of ARID1A expression [17–20]. Although the relationship between cancer and endometriosis remains unclear, some researchers have posited that endometriosis-associated ovarian carcinoma should be considered a distinct clinical entity [9, 21].

Most patients with carcinomas that arise from endometriotic cysts are diagnosed at Stage I of the disease because of associated symptoms such as pelvic pain. This study aimed to determine the prognostic significance and characteristics of Stage I endometrioid and clear cell subtypes of EOC originating from endometriotic cysts.

Materials and methods

This study included patients diagnosed as ovarian carcinoma between 2007 and 2017 at Baskent University, School of Medicine, Department of Obstetrics and Gynecology, Division of Gynecologic Oncology, Ankara, Turkey. The electronic files of patients that were diagnosed with ovarian cancer were retrospectively reviewed. Of the 108 patients identified with ovarian endometrioid or clear cell ovarian

adenocarcinoma, 78 (72.2%) had Stage I cancer and were included in the study.

78 patients were divided into three groups based on pathology findings as follows:

- Group 1: Patients with cancers arising from endometriotic cysts.
- Group 2: Patients with ovarian and pelvic endometriosis.
- Group 3: Patients without endometriosis.

Cancer was considered to have originated from endometriotic cysts based on evidence of malignant transition in these cysts, and the presence of a junction between a normal-appearing cyst epithelium and the carcinoma. Patients with endometriosis that did not meet these criteria for cancer arising from endometriosis constituted the second group (pelvic endometriosis).

Clinicopathological data were compared among groups, as shown in Table 1. Moreover, synchronous tumors of the ovaries and endometrium were identified and analyzed. All specimens that originated from endometriotic cysts had a cystic macroscopic appearance and were re-evaluated by an experienced gynecopathologist (Author 3). The survival status of each patient was determined as dead or alive at the median follow-up time. According to the hospital's protocol, all patients underwent standard cytoreductive surgery, including total abdominal hysterectomy, bilateral salpingo-oophorectomy, bilateral pelvic and para-aortic lymph node dissection, and omentectomy. None of the patients required

Table 1 Characteristics of patients with stage I ovarian endometrioid and clear cell carcinoma that arose from endometriotic cysts, with and without pelvic endometriosis

	Arose from endometriotic cysts <i>n</i> (%)	With pelvic endometriosis <i>n</i> (%)	Without endometriosis <i>n</i> (%)	Total <i>n</i> (%)	<i>p</i>
Patients	39 (50%)	13 (16.7)	26 (33)	78 (100)	
Age (years \pm SD)	46.1 \pm 9.6	54 \pm 13	48.3 \pm 10.2		0.39
Ca 125 U mL ⁻¹ (mean \pm SD)	97 \pm 45	99 \pm 60	126 \pm 80		0.97
Histology					
Clear cell	23 (62.1)	5 (13.6)	9 (24.3)	37 (47.4)	0.12
Endometrioid	16 (39)	8 (19.6)	17 (41.4)	41 (52.6)	
Capsule rupture (+)	12 (44.4)	5 (18.6)	10 (37)	27 (35.5)	0.7
Cytology (+)	2 (33.3)	1 (16.7)	3 (50)	6 (7.8)	0.76
Grade (endometrioid)					
Grade I	8 (40)	6 (30)	6 (30)	20 (48.8)	
Grade II	5 (41.6)	2 (6.8)	5 (41.6)	12 (29.3)	0.44
Grade III	3 (33.3)	0	6 (66.6)	9 (22)	
Stage					
Stage IA	22 (61.1)	6 (16.6)	8 (22.3)	36 (46.2)	0.22
Stage IC	17 (40.4)	7 (16.6)	18 (43)	42 (47.8)	
Synchronous tumor	4 (30.7)	2 (15.3)	7 (64)	13 (16.7)	0.2
Number of patients who received chemotherapy	30 (76.9)	10 (76.9)	21 (80.9)	61 (80.2)	0.98

extensive surgery. Following surgery, patients received paclitaxel and carboplatin chemotherapy regimen based on their FIGO stage and histologic subtype. Instances of recurrence were confirmed via computerized tomography (CT) scans and elevated serum CA 125 levels. Statistical analysis was performed using SPSS for Mac. Between-group comparisons were made using the Chi square or Fisher's exact test. Survival analysis was conducted using the log-rank test and adjusted Kaplan–Meier model. The level of statistical significance was set at $p < 0.05$ done.

Results

The study included 78 patients that met the inclusion criteria. Of the 78 patients with ovarian endometrioid and clear cell adenocarcinoma, 39 (50%) had tumors that originated from endometriotic cysts (group 1), 13 (16.7%) had pelvic endometriosis (group 2), and 26 (33.3%) did not have endometriosis (group 3). Patient and tumor characteristics are summarized in Table 1. The mean age of the patients in group 1 was 46.1 ± 9.6 years, compared to 54 ± 13 years in group 2 and 48.3 ± 10.2 years in group 3.

Of all the patients in the study, 37 (47.4%) had clear cell adenocarcinoma, of which 23 (62%) had cancer arising from endometriotic cysts. In addition, 41 (52.6%) of the 78 patients included in this study had ovarian endometrioid adenocarcinoma, of which 16 (39%) had cancer originating from endometriotic cysts. Tumor grade did not differ significantly between these patients ($p = 0.44$).

Furthermore, 36 (46.2%) patients were diagnosed as Stage IA cancer, of which 22 (61.1%) had cancer that originated from endometriotic cysts, 6 (16.6%) had endometriosis, and 8 (22.3%) did not have endometriosis. This relationship was not significant ($p = 0.22$). Synchronous tumors were noted in 13 patients with endometrioid adenocarcinoma of uterus. The number of such tumors in each of the 13 patients did not differ significantly ($p = 0.2$).

Adjuvant chemotherapy following primary surgery was administered in 61 (78.2%) of the patients, and 17 patients with Stage IA endometrioid adenocarcinoma were followed up. In addition, two patients who received a paclitaxel and carboplatin regimen had platinum resistance.

The median follow-up time was 60.2 months (range: 5–125 months). The 5-year overall survival (OS) rate was 94.9% and the progression-free survival (PFS) rate was 92.3% for all patients. The difference in survival rates among the groups was not statistically significant ($p = 0.4–0.6$) (Figs. 1 and 2).

In total, six patients had a recurrence and four patients died during follow-up. Subgroup analysis according to disease staging and histology also showed that there was no significant difference in 5-year OS and DFS. Results of subgroup analysis are given in Tables 2 and 3.

Discussion

This study aimed to determine the characteristics and prognostic significance of early stage clear cell and ovarian endometrioid adenocarcinomas arising from endometriotic

Fig. 1 5-year overall survival curves of patients with stage I ovarian endometrioid and clear cell carcinoma arose from endometriotic cysts and with or without pelvic endometriosis

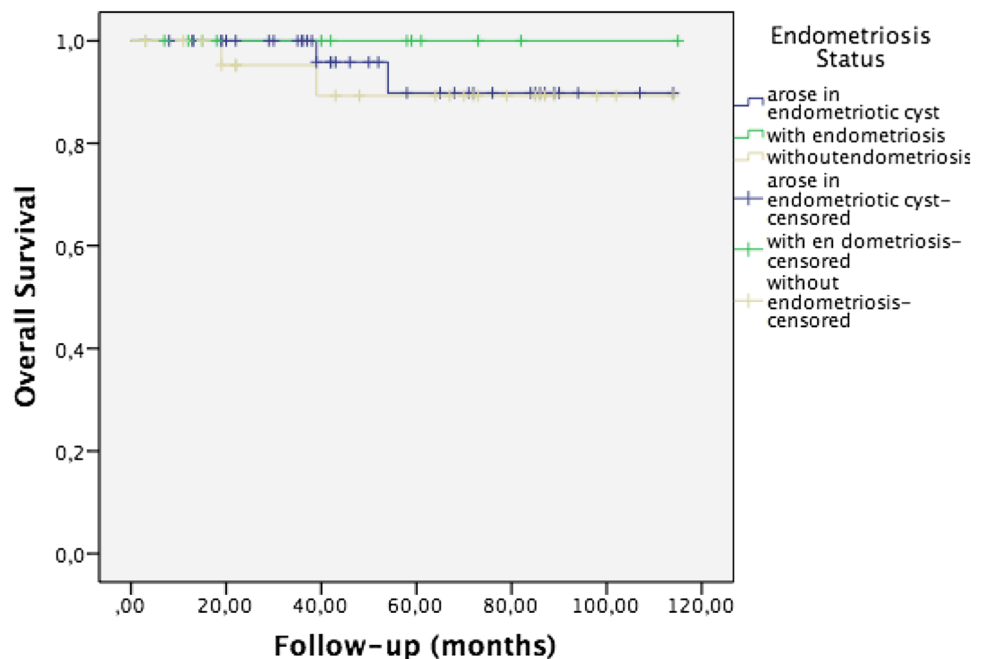


Fig. 2 5-year disease-free survival curves of patients with stage I ovarian endometrioid and clear cell carcinoma arose from endometriotic cysts and with or without pelvic endometriosis

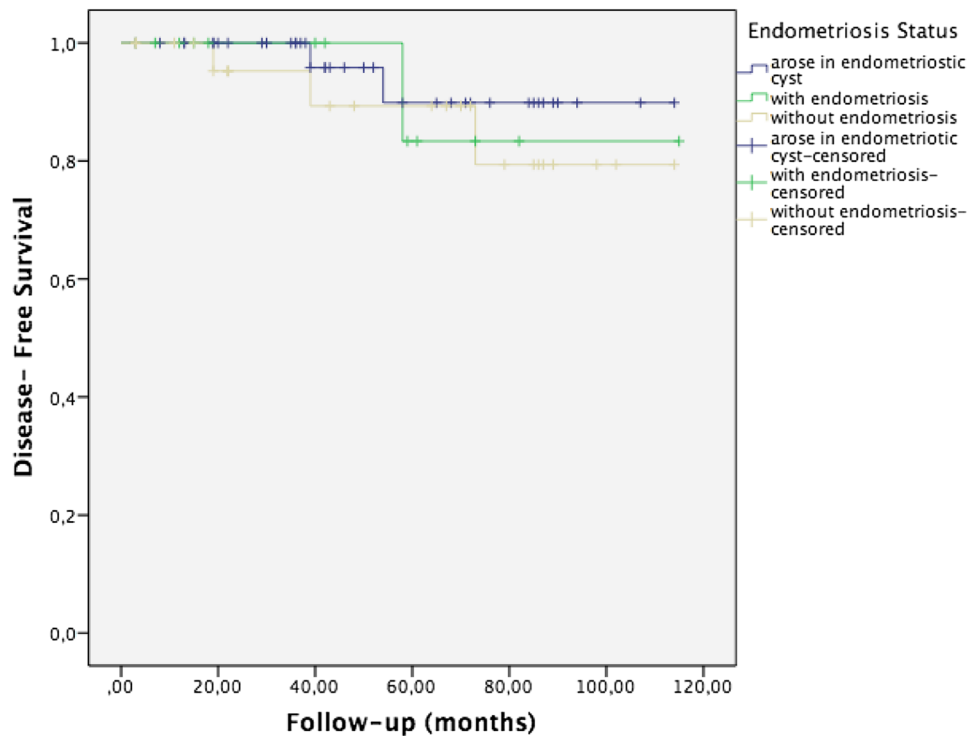


Table 2 Recurrence and death according to disease stage and endometriosis status in patients with ovarian endometrioid adenocarcinoma

	<i>n</i>	Death	Recurrence	<i>p</i>
Arose in endometriotic cyst				
Stage 1A	9	0/9	0/9	0.92
Stage 1C	7	0/7	0/7	0.87
Total	16	0/16	0/16	
With pelvic endometriosis				
Stage 1A	3	0/3	1/3	0.91
Stage 1C	5	0/5	0/5	0.88
Total	8	0/8	1/8	
Without endometriosis				
Stage 1A	5	0/5	0/5	0.75
Stage 1C	12	1/12	2/12	0.82
Total	17	1/17	2/12	
Total	41	1/41	3/41	

Table 3 Recurrence and death according to disease stage and endometriosis status in patients with ovarian clear cell carcinoma

	<i>n</i>	Death	Recurrence	<i>p</i>
Arose in endometriotic cyst				
Stage 1A	13	2/13	2/13	0.72
Stage 1C	10	0/10	0/10	0.81
Total	23	2/23	2/23	
With pelvic endometriosis				
Stage 1A	3	0/3	0/3	0.91
Stage 1C	2	0/2	0/2	0.86
Total	5	0/5	0/5	
Without endometriosis				
Stage 1A	3	0/3	0/3	0.79
Stage 1C	6	1/6	1/6	0.81
Total	9	1/9	1/9	0.83
Total	37	3/37	3/37	

cysts. The overall rate of EOC originating from endometriotic cysts was 42.5% (46/108) among patients with clear cell and endometrioid EOC, and 7.3% (57/780) among all EOC patients. We determined concurrent, coincidental, and co-existing endometriosis as a distinct group.

In this study, endometriosis and endometriotic cysts were not observed to be risk factors for synchronous endometrial cancer ($p = 0.2$). Additionally, there were no significant differences in 5-year OS, DFS, or recurrence

based on if the origin was from endometriotic cysts or not. Moreover, tumor grade in-patients with endometrioid adenocarcinoma were similar. Furthermore, evaluation of endometrioid and clear cell histological subtypes was conducted separately for subgroup analysis. Also, 5-year OS, DFS and recurrence rates were all similar. In this study, endometriosis was not a prognostic factor. This study is unique and uniform because of its inclusion criteria. Only patients with Stage I EOC originating from endometriotic cysts were included to ensure uniformity. Patients with

ovarian and pelvic endometriosis constituted a separate group (group 2).

Patients with endometriosis-associated ovarian cancer tend to be younger, have a high incidence of Stage I disease, have a lower incidence of lymph node metastasis and display lower positive peritoneal cytology [10–16]. However, mean patient age, number of patients with positive cytology, and the median CA 125 level were similar across the three groups in our study. This may be a result of considering pelvic endometriosis as a distinct group.

Endometriosis was believed to be a good prognostic factor by some authors [10, 16, 22, 23]. However, the term “arising in endometriosis” is not clear. Many authors classified concurrent endometriosis under the umbrella of cancers arising in endometriosis. For example, a recent study from Korea reported longer disease-free survival (DFS) (87% vs. 95%) and greater OS (70% vs. 76%), even in Stage I disease for patients with endometriosis [22]. Subgroup analysis conducted based on disease stage yield comparable results to our study. However, authors classified endometriosis occurring elsewhere in the ovary as originating from endometriosis.

The belief that endometriosis is a good prognostic factor has now been challenged by some authors. In these studies, FIGO stage continued to be the most important prognostic factor [10–14]. This is one of the reasons why only Stage I patients were included in our study. Wang et al. [13] conducted a 12-year cohort study that included 188 patients with endometrioid EOC, of which 32 (17%) had endometriosis. The patients with endometriosis had better OS (96.9% vs. 84%, $p=0.027$), and had lower recurrence and mortality rates (18.8% vs. 56.4%, $p<0.001$). Nonetheless, multivariate analysis showed that menopausal status and FIGO stage were the only independent predictors of OS. Furthermore, the researchers analyzed concurrent endometriosis and defined endometriosis-associated ovarian cancer as the presence of endometriosis in the same ovary, a contralateral ovary, or in extra-ovarian tissue. However, it is difficult to compare our study’s results with those from Wang et al. [13] due to differences in inclusion criteria, and our study’s focus on cancers arising from endometriotic cysts.

A recent nationwide study from Denmark reported shorter OS in ovarian clear cell carcinoma patients with pelvic endometriosis. The researchers included patients with ovarian clear cell carcinoma of any stage and divided them into three groups according to endometriosis status as follows: ovarian endometriosis (ipsilateral or contralateral ovary), pelvic endometriosis and, no endometriosis. The study reported that there was no difference in OS between the groups, but patients with pelvic endometriosis had poorer prognosis than those without endometriosis. Although the study included a satisfactory number of patients from this unique population, it did not report

the macroscopic appearance of ovarian endometriosis, and included patients with contralateral ovarian endometriosis in the ovarian endometriosis group [24]. In contrast, our study classified patients with contralateral ovarian endometriosis as having co-existing endometriosis. Furthermore, cancers that originated from endometriotic cysts had a cystic macroscopic appearance (endometrioma).

Kumar et al. [11] reported a higher 5-year OS rate in patients with endometriosis-associated EOC (62% vs. 51%, $p=0.038$). Their study included 226 EOC patients, of which 42 had endometriosis. Remarkably, 23 (54.8%) of the 42 patients with endometriosis and 148 (80.4%) of the 184 patients in the non-endometriotic group displayed serous histology. They also reported that based on multivariate analysis, endometriosis did not have a significant effect on survival ($p=0.3$). Additionally, their subgroup analysis showed that the difference in survival between Stage I patients with and without endometriosis was not significant ($p=0.18$).

A recent Italian study reported that patients with ovarian clear cell adenocarcinoma originating from endometriotic cysts did not have any survival advantage, compared to patients in the non-endometriotic group [15]. In contrast, another Italian study by Orezza et al. [10] reported that the presence of endometriosis in patients with ovarian clear cell carcinoma is associated with a good prognosis. Cuff et al. [12] studied 144 ovarian cancer patients with clear cell, endometrioid, and mixed histology carcinomas, and observed that the best overall predictor of DFS was FIGO stage at presentation ($p<0.001$). Moreover, they reported that endometriosis was not significantly correlated with DFS ($p=0.7$). A meta-analysis by Kim et al. [14] that included 20 case–control and 15 cohort studies showed that EOC associated with endometriosis has a similar OS and DFS as EOC not associated with endometriosis.

In conclusion, our study’s findings indicate that patients with early stage ovarian clear cell carcinoma and endometrioid adenocarcinoma that arose from endometriotic cysts are not clinicopathologically very different to patients with non-endometriotic carcinomas.

Based on this, clinicians should not consider endometriosis as a good prognostic factor. Furthermore, it is premature to consider cancers that arise from endometriotic cysts as a distinct entity. Additional research, particularly focused on molecular biology and genetics, is needed to clarify this relationship.

Author contributions AA: project development, data collection and management, data analysis, manuscript writing, and editing. HA: project development, data collection, manuscript writing, and literature search. NH: data analysis and editing.

Compliance with ethical standards

Conflict of interest The authors declare there are no conflicts of interest—financial or otherwise—related to the material presented herein.

Ethics approval Ethical approval for the present study was not required, as it was retrospectively performed.

References

- Redwine DB (1999) Ovarian endometriosis: a marker for more extensive pelvic and intestinal disease. *Fertil Steril* 72(2):310–315
- Kobayashi H, Sumimoto K, Moniwa N, Imai M, Takakura K, Kuromaki T et al (2007) Risk of developing ovarian cancer among women with ovarian endometrioma: a cohort study in Shizuoka, Japan. *Int J Gynecol Cancer* 17(1):37–43
- Ogawa S, Kaku T, Amada S, Kobayashi H, Hirakawa T, Ariyoshi K et al (2000) Ovarian endometriosis associated with ovarian carcinoma: a clinicopathological and immunohistochemical study. *Gynecol Oncol* 77(2):298–304
- Melin A, Sparen P, Persson I, Bergqvist A (2006) Endometriosis and the risk of cancer with special emphasis on ovarian cancer. *Hum Reprod* 21(5):1237–1242
- Kondi-Pafiti A, Papakonstantinou E, Iavazzo C, Grigoriadis C, Salakos N, Gregoriou O (2012) Clinicopathological characteristics of ovarian carcinomas associated with endometriosis. *Arch Gynecol Obstet* 285(2):479–483
- Qiu L, Wang S, Lang JH, Shen K, Huang HF, Pan LY et al (2013) The occurrence of endometriosis with ovarian carcinomas is not purely coincidental. *Eur J Obstet Gynecol Reprod Biol* 170(1):225–228
- Brinton LA, Lamb EJ, Moghissi KS, Scoccia B, Althuis MD, Mabie JE et al (2004) Ovarian cancer risk associated with varying causes of infertility. *Fertil Steril* 82(2):405–414
- Pearce CL, Templeman C, Rossing MA, Lee A, Near AM, Webb PM et al (2012) Association between endometriosis and risk of histological subtypes of ovarian cancer: a pooled analysis of case-control studies. *Lancet Oncol* 13(4):385–394
- Van Gorp T, Amant F, Neven P, Vergote I, Moerman P (2004) Endometriosis and the development of malignant tumours of the pelvis. A review of literature. *Best Pract Res Clin Obstet Gynaecol* 18(2):349–371
- Orezzoli JP, Russell AH, Oliva E, Del Carmen MG, Eichhorn J, Fuller AF (2008) Prognostic implication of endometriosis in clear cell carcinoma of the ovary. *Gynecol Oncol* 110(3):336–344
- Kumar S, Munkarah A, Arabi H, Bandyopadhyay S, Semaan A, Hayek K et al (2011) Prognostic analysis of ovarian cancer associated with endometriosis. *Am J Obstet Gynecol* 204(1):63 e1–63 e7
- Cuff J, Longacre TA (2012) Endometriosis does not confer improved prognosis in ovarian carcinoma of uniform cell type. *Am J Surg Pathol* 36(5):688–695
- Wang S, Qiu L, Lang JH, Shen K, Huang HF, Pan LY et al (2013) Prognostic analysis of endometrioid epithelial ovarian cancer with or without endometriosis: a 12-year cohort study of Chinese patients. *Am J Obstet Gynecol* 209(3):241 e1–241 e9
- Kim HS, Kim TH, Chung HH, Song YS (2014) Risk and prognosis of ovarian cancer in women with endometriosis: a meta-analysis. *Br J Cancer* 110(7):1878–1890
- Scarfone G, Bergamini A, Noli S, Villa A, Cipriani S, Taccagni G et al (2014) Characteristics of clear cell ovarian cancer arising from endometriosis: a two center cohort study. *Gynecol Oncol* 133(3):480–484
- Melin A, Lundholm C, Malki N, Swahn ML, Sparen P, Bergqvist A (2011) Endometriosis as a prognostic factor for cancer survival. *Int J Cancer* 129(4):948–955
- Ali-Fehmi R, Khalifeh I, Bandyopadhyay S, Lawrence WD, Silva E, Liao D et al (2006) Patterns of loss of heterozygosity at 10q23.3 and microsatellite instability in endometriosis, atypical endometriosis, and ovarian carcinoma arising in association with endometriosis. *Int J Gynecol Pathol* 25(3):223–229
- Ayhan A, Mao TL, Seekin T, Wu CH, Guan B, Ogawa H et al (2012) Loss of ARID1A expression is an early molecular event in tumor progression from ovarian endometriotic cyst to clear cell and endometrioid carcinoma. *Int J Gynecol Cancer* 22(8):1310–1315
- Mangili G, Bergamini A, Taccagni G, Gentile C, Panina P, Vigano P et al (2012) Unraveling the two entities of endometrioid ovarian cancer: a single center clinical experience. *Gynecol Oncol* 126(3):403–407
- Munksgaard PS, Blaakaer J (2012) The association between endometriosis and ovarian cancer: a review of histological, genetic and molecular alterations. *Gynecol Oncol* 124(1):164–169
- Ye S, Yang J, You Y et al (2014) Comparative study of ovarian clear cell carcinoma with and without endometriosis in People's Republic of China. *Fertil Steril* 102:1656Y1662
- Park JY, Kim DY, Suh DS, Kim JH, Kim YM, Kim YT et al (2018) Significance of ovarian endometriosis on the prognosis of ovarian clear cell carcinoma. *Int J Gynecol Cancer* 28(1):11–18
- Modesitt SC, Tortolero-Luna G, Robinson JB, Gershenson DM, Wolf JK (2002) Ovarian and extraovarian endometriosis-associated cancer. *Obstet Gynecol* 100(4):788–795
- Schnack TH, Hogdall E, Thomsen LN, Hogdall C (2017) Demographic, clinical, and prognostic factors of ovarian clear cell adenocarcinomas according to endometriosis status. *Int J Gynecol Cancer* 27(9):1804–1812