

# Pathogenesis of endometriosis: the genetic/epigenetic theory

Philippe R. Koninckx, M.D., Ph.D.,<sup>a,b,c,d</sup> Anastasia Ussia, M.D.,<sup>b,d</sup> Leila Adamyan, M.D., Ph.D.,<sup>e</sup> Arnaud Wattiez, M.D., Ph.D.,<sup>c,f</sup> Victor Gomel, M.D.,<sup>g</sup> and Dan C. Martin, M.D.<sup>h</sup>

<sup>a</sup> Obstetrics-Gynecology, KU Leuven, Bierbeek, Belgium; <sup>b</sup> Gruppo Italo Belga, Rome, Italy; <sup>c</sup> Latiffa Hospital, Dubai, United Arab Emirates; <sup>d</sup> Università Cattolica, Roma Italy; <sup>e</sup> Department of Operative Gynecology, Federal State Budget Institution V. I. Kulakov Research Centre for Obstetrics, Gynecology, and Perinatology, Ministry of Health of the Russian Federation, and Department of Reproductive Medicine and Surgery, Moscow State University of Medicine and Dentistry, Moscow, Russia; <sup>f</sup> Department of Obstetrics and Gynecology, University of Strasbourg, Strasbourg, France; <sup>g</sup> Department of Obstetrics and Gynecology, University of British Columbia and Women's Hospital, Vancouver, British Columbia, Canada; and <sup>h</sup> School of Medicine, University of Tennessee Health Science Center, Memphis, Tennessee, and Virginia Commonwealth University, Richmond, Virginia

**Objective:** To study the pathophysiology of endometriosis.

**Design:** Overview of observations on endometriosis.

**Setting:** Not applicable.

**Patient(s):** None.

**Interventions(s):** None.

**Main Outcome Measure(s):** The hypothesis is compatible with all observations.

**Result(s):** Endometriosis, endometrium-like tissue outside the uterus, has a variable macroscopic appearance and a poorly understood natural history. It is a hereditary and heterogeneous disease with many biochemical changes in the lesions, which are clonal in origin. It is associated with pain, infertility, adenomyosis, and changes in the junctional zone, placentation, immunology, plasma, peritoneal fluid, and chronic inflammation of the peritoneal cavity. The Sampson hypothesis of implanted endometrial cells following retrograde menstruation, angiogenic spread, lymphogenic spread, or the metaplasia theory cannot explain all observations if metaplasia is defined as cells with reversible changes and an abnormal behavior/morphology due to the abnormal environment. We propose a polygenetic/polyepigenetic mechanism. The set of genetic and epigenetic incidents transmitted at birth could explain the hereditary aspects, the predisposition, and the endometriosis-associated changes in the endometrium, immunology, and placentation. To develop typical, cystic ovarian or deep endometriosis lesions, a variable series of additional transmissible genetic and epigenetic incidents are required to occur in a cell which may vary from endometrial to stem cells. Subtle lesions are viewed as endometrium in a different environment until additional incidents occur. Typical cystic ovarian or deep endometriosis lesions are heterogeneous and represent three different diseases.

**Conclusion(s):** The genetic epigenetic theory is compatible with all observations on endometriosis. Implications for treatment and prevention are discussed. (*Fertil Steril*® 2019;111:327–40. ©2018 by American Society for Reproductive Medicine.)

**El resumen está disponible en Español al final del artículo.**

**Key Words:** Endometriosis, pathogenesis, classification, heredity, genetics, epigenetics

**Discuss:** You can discuss this article with its authors and other readers at <https://www.fertstertdialog.com/users/16110-fertility-and-sterility/posts/39465-26548>

The word endometriosis was introduced by Sampson in 1927 (1, 2) based on the description of endometrium-like tissue in the myometrium by Rokitansky (3), in the rectovaginal septum by Cullen, who

called this entity an adenomyoma (4–7), and in “hemorrhagic (chocolate) cysts in the ovaries” (8). Endometriosis was defined as “endometrium-like glands and stroma outside the uterus.” Therefore, stromatosis (9) and

müllerianosis (10) are not considered to be endometriosis despite similarities.

Endometriosis is an enigmatic disease. Understanding the pathophysiology is important in prevention, diagnosis, and therapy. There is no nonhuman animal model with sufficient similarity to the human myometrium, junctional zone (JZ), endometrium, placentation, and pregnancy disorders, such as preeclampsia. In the absence of experimentation, our views on the pathophysiology of endometriosis are limited to clinical,

Received June 23, 2018; revised October 16, 2018; accepted October 17, 2018; published online December 7, 2018.

P.R.K. has nothing to disclose. A.U. has nothing to disclose. L.A. has nothing to disclose. A.W. has nothing to disclose. V.G. has nothing to disclose. D.C.M. has nothing to disclose.

Reprint requests: Philippe R. Koninckx, M.D., Ph.D., Vuilenbos 2, 3360 Bierbeek, Belgium (E-mail: [pkoninckx@gmail.com](mailto:pkoninckx@gmail.com)).

*Fertility and Sterility*® Vol. 111, No. 2, February 2019 0015-0282/\$36.00

Copyright ©2018 American Society for Reproductive Medicine, Published by Elsevier Inc.

<https://doi.org/10.1016/j.fertnstert.2018.10.013>

histologic, and biochemical observations and to research on endometriotic tissues.

To describe the genetic/epigenetic theory of endometriosis, we will summarize the observations made and review the theories on pathophysiology as they were developed over the last century (Table 1).

## OBSERVATIONS IN ENDOMETRIOSIS

Endometriosis has a variable appearance. Reports on endometriosis describe lesions found during surgery which were initially severe lesions in the pelvis (3–7), the ovary (8), and other organs. Although smaller black puckered “powder burn” superficial peritoneal lesions in sclerotic areas had been described, the high prevalence of these typical lesions in women with pain and infertility was realized only after the introduction of laparoscopy in the 1970s. Nonpigmented lesions had been described (8, 11–14), but their high prevalence was realized only in 1986 (15). The observation that retrograde menstruation occurred in almost all women (16, 17) started the search for early and small lesions that were subsequently called subtle lesions (18, 19). Microscopic endometriosis lesions were found in the peritoneum and later in lymphoid glands and in the bowel at a distance from deep endometriosis (20).

“Deep endometriosis” was described in 1990 as deeper lesions with a microscopic appearance of adenomyosis externa, with glands in phase with the endometrium and associated with severe pain (21). These lesions are generally unique, larger than 1 cm in diameter, with frequent invasion into the muscle of the bowel wall, and with occasional nerve invasion (22), a neurotropic effect (23, 24), and some 20% lymph node involvement (25, 26). The definition of deep endometriosis as lesions deeper than 5 mm under the

peritoneum was later suggested because the biphasic frequency distribution of depth of lesions (27) indicated two populations overlapping at 6 mm of depth (Fig. 1). A second argument was that at depths greater than 5 mm, glands were more active (28), which was considered to be compatible with a depth where the effect of the progesterone concentrations in peritoneal fluid was less important (29). This change from a histologic definition to a 5-mm-depth definition remains a cause of confusion, because depth is an inaccurate surgical estimation, permitting some typical lesions to fit the 5 mm definition.

Endometriosis occasionally occurs in women without an endometrium (30, 31) and in men (32, 33). Endometriosis is a hereditary disease. The risk of developing endometriosis is 6%–9% higher in first-degree relatives of women with endometriosis (34, 35) and 15% higher when they had severe disease (36, 37). Familial clustering of endometriosis was demonstrated in humans (38) and other primates (39). In twin sisters, the prevalence (40–43) and the age of onset (44) of endometriosis are similar. More recently, hereditary factors were estimated to account for 50% of endometriosis (45–47).

We are far from understanding the molecular mechanisms (48). Genome-wide scanning and linkage analysis did not identify the genes involved (49). Linkage analysis found two loci but the logarithm of odds scores were low. Genome-wide association studies identified 10 (50) or 15 (51) loci with single-nucleotide polymorphisms (52) associated with severe endometriosis, but located in DNA sequences regulating target genes (53). A recent meta-analysis identified five loci regulating sex steroid hormone pathways, five secondary signals, and 19 single-nucleotide polymorphisms robustly associated with endometriosis (54). All studies that investigated a specific hereditary predisposition as detoxication failed (55).

The natural history of endometriosis is not clear. Endometriosis is considered to be a progressive disease because larger lesions must have developed over some period. However, progression of subtle lesions or progression from typical to cystic or deep lesions has not been observed directly (56). In addition, regression of smaller lesions is common (57). Clinically, endometriotic lesions, especially rectovaginal deep endometriosis lesions do not grow rapidly (58) when surgery is not performed. It is unclear whether endometriosis is a recurrent disease (59). Studies generally describe recurrence of symptoms instead of recurrence of lesions (60). Recurrence rates of cystic ovarian endometriosis after stripping are less than 20% within 6 months (61, 62) but vary with the surgeon (63) and the technique used. Recurrence rates of deep endometriosis lesions after complete excision are rare (personal observations) (60). The recurrence rates of typical lesions and subtle lesions are thought to be higher, although the data are limited.

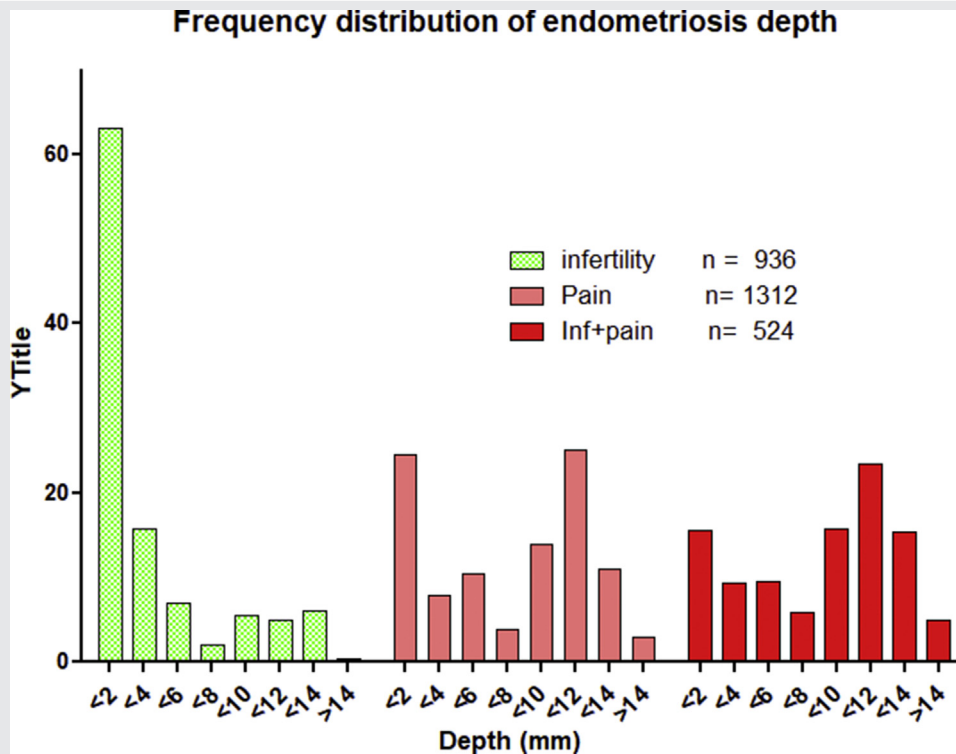
The epidemiology of endometriosis is unclear. Laparoscopic recognition varies with the expertise of the surgeon. Hospital-based discharge records are therefore hampered by diagnostic uncertainties (64). Clinical observations suggest that the prevalence and severity of deep endometriosis have markedly increased during the past 20 years (58). Subtle endometriosis lesions decrease with age, whereas typical, cystic, and deep lesions increase with age, at least until menopause (58).

**TABLE 1**

### Clinical observations on endometriosis.

1. Variable appearance (subtle-typical-cystic-deep)
  2. Occurs also in women without endometrium and in men
  3. A hereditary disease and predisposition
  4. Natural history:
    - Most subtle lesions do not progress
    - Most typical-cystic-deep lesions are not progressive after diagnosis
    - Most typical-cystic-deep lesions are not recurrent after surgery
  5. Epidemiology of endometriosis
  6. A heterogeneous disease
  7. Endometriosis is associated with:
    - Pain and infertility
    - Adenomyosis
    - Changes in plasma
    - Changes in peritoneal fluid
    - Changes in endometrium
    - Changes in pregnancy outcome
    - Pelvic infections
    - Cancer risk
    - Total body radiation and dioxin intake
  - The endometriosis lesion:
    8. Clonal
    9. Altered biology, e.g., estrogen formation and progesterone resistance
- Koninckx. Pathogenesis of endometriosis. Fertil Steril 2018.*

FIGURE 1



Frequency distribution of the depth of endometriosis lesions in women with infertility, with pain, and with both pain and infertility, as observed during surgical excision. The data, extracted from the Leuven database spanning the years 1990–2010, confirm and extend previous data (27) and illustrate the overlap between the two populations of more superficial (typical lesions) and deeper adenomyosis externa lesions.

Koninckx. Pathogenesis of endometriosis. *Fertil Steril* 2018.

Endometriosis is a heterogeneous disease. Although most women with deep endometriosis have severe pain, especially during menstruation (65), some large lesions (estimated to be 5%) are not painful. Most deep endometriosis lesions do not (or very slowly) progress over time, but some lesions can be fast progressive (unpublished observations). Estrogens stimulate growth, whereas progestogen therapy and pregnancy stop growth or cause decidualization and decrease endometriosis-associated pain. However, some endometriosis lesions behave differently. Bowel perforations have been reported during pregnancy (66, 67) and estrogen-progestin treatment (68). During pregnancy, polypoid bladder lesions (69), bladder perforations (70), and peritoneal bleeding (71) occur. Growth has been observed in men (32) and in postmenopausal women (72) without increased circulating estrogen concentrations.

### OTHER OBSERVATIONS ASSOCIATED WITH ENDOMETRIOSIS

Endometriosis is thought to be associated with pain and infertility. However, it is unclear whether microscopic endometriosis (20) and subtle lesions cause pain or infertility, given the high prevalence in women with infertility only and women with pain only (27). Typical endometriosis is estimated to cause minor pain in 50% of affected women, and in women

with infertility only, one-half of them are estimated to have typical lesions (27). Cystic ovarian endometriosis causes pain in more than 80%, and deep endometriosis causes severe pain in the large majority of women (27). Notwithstanding the 30%–50% cumulative pregnancy rates after surgical excision (73), it remains unclear whether and how typical and deep endometriosis cause infertility. That cystic ovarian endometriosis is a cause of infertility is not surprising, because it is associated with adhesions.

Despite the widely held belief of the association of endometriosis with adenomyosis, the data demonstrating this association are limited (74). Focal adenomyotic nodules are more frequent in women with deep endometriosis (75, 76).

In plasma of women with endometriosis, numerous reports have identified changes in immunology (77–85), lymphocytes (86), prostaglandins (87), and insulin-like growth factor I (88). That the low natural killer (NK) cell activity in plasma remains low whereas the elevated CA-125 concentrations return to normal after surgical excision of deep endometriosis suggests that the NK cell defect is a cause and the elevated CA-125 a consequence of endometriosis (89).

Peritoneal fluid of women with endometriosis and the luteinized unruptured follicle syndrome has much lower concentrations of estrogens and progesterone after ovulation (29). The peritoneal fluid exhibits low-grade inflammation with a high number of activated macrophages (90), changes

in cytokines (91–95), growth factors, acylcarnitines, phosphatidylcholines, and sphingomyelins (96), vascular epithelial growth factor (97, 98), and other angiogenic factors (99–118), especially of the transforming growth factor  $\beta$  superfamily (119). The concentrations of CA-125 and glycodelin are greatly elevated (120). More retrograde menstruation (121) would increase the retraction of peritoneal mesothelial cells, thus facilitating the implantation of endometrial cells (122, 123).

In the endometrium of women with endometriosis several hundred minor biochemical changes have been described (124–128). Contractility of the uterus is modified in women with deep endometriosis or adenomyosis (129).

Endometriosis, especially cystic ovarian and deep endometriosis (130, 131), and adenomyosis (132, 133) are associated with abnormal placentation, insufficient physiologic changes in the spiral arteries, and an increased risk of preterm birth, small for gestational age (SGA) babies, and preeclampsia (131).

Endometriosis is associated with higher concentrations of *Escherichia coli* in menstrual blood (134, 135), with vaginal infections (136), and with chronic endometritis (137). The low-grade pelvic inflammation in endometriosis was postulated to be a consequence of an initial infection and subsequent sterile inflammation (78). High-risk papillomavirus infection and Mollicutes are found more frequently in ovaries of women with cystic ovarian endometriosis (138) and in peritoneal fluid, respectively.

Endometriosis seems associated with a higher risk of cancer, as recently reviewed (139, 140). The association with ovarian cancer remains debated (141). Dioxin (142–145) and total body radiation (146, 147) are suggested to be associated with endometriosis. Both can have genomic or epigenetic (148) effects. In addition, the endometriosis that develops after total body radiation in nonhuman primates develops after a delay of 5 years, which suggests a genomic effect.

Endometriosis lesions are clonal, as demonstrated for typical (149), deep (150), and cystic ovarian (151–153) endometriosis. Multifocal, monoclonal lesions in one woman may derive from different progenitor cells (149).

Endometriosis lesions have an altered biology. Local estrogen production (154) and progesterone resistance (155–162) were demonstrated in larger endometriosis lesions (154–163). Numerous biochemical changes exist, such as mitogen-activated protein kinase (164), transcription-3 signaling (165), genetic variants expression (166), the Hoxa10/HOXA10 gene (167), cytokines (168–171), dendritic cells (172), vitamin D (173), mast cells (174, 175), hypoxia-inducible factor (176), high Mobility Group Box 1 and Toll-Like Receptor 4 (177), matrix metalloproteinase promoter polymorphisms (178), galectin-3 expression (179), promoter polymorphisms of matrix metalloproteinases genes (180), progesterone receptor expression (181), GF-I (182), myostatin and activin II receptor expression (183), Smad3/4 (184) or leptin (185) stimulated activation of aromatase activity, and expression of numerous cancer-associated mutations (186, 187). These changes are increasingly viewed as a consequence of genetic or epigenetic polymorphism (154, 188–190). Other epigenetic changes (191–196) comprise

methylation, demethylation of DNA and modifications in histone code (193, 197, 198).

## THE PATHOGENESIS OF ENDOMETRIOSIS: THE GENETIC/EPIGENETIC THEORY

### Historical Background

The pathophysiology of the adenomyomas described by Cullen (4–7) was suggested by Meyer (199) and later by Gruenwald (31) to be due to metaplasia. Another hypothesis was the development from müllerian remnants (200).

Sampson (1, 11, 201) proposed retrograde menstruation as the cause of cystic ovarian endometriosis. Retrograde menstruation is an attractive hypothesis because menstrual fluid contains living cells, demonstrated already in 1927 (202), with implantation and growth potential as demonstrated in 1958 by means of subcutaneous injection (203) and by growth in vitro and on the chicken allantoic membrane (204). For the latter, tissue integrity is important (204). The implantation of endometrial fragments was directly observed (205) in a neonate. Also pelvic endometriosis is more frequently found on the left side of the pelvis (206, 207) and on the right side of the diaphragm, which is compatible with gravity and with the clockwise circulation of peritoneal fluid. Microscopic and subtle lesions are considered to be the initial stages after implantation. Neonatal menstruation (208–211), occurring in some 5% of neonates (208, 212–217), especially in postmature and SGA babies, might explain premenarchal and severe adolescent (218, 219) endometriosis. The behavior of endometriosis lesions and the aromatase activity or progesterone resistance are speculated to be caused by an abnormal environment, by immunology, or by implantation of basal endometrium (163). The retrograde menstruation and implantation theory does not explain all clinical observations (Table 1), such as extragenital endometriosis (220), endometriosis in women without endometrium (31) and in men (33), or the clonal aspect (149).

The mesothelial cell metaplasia theory, proposed in 1942 (31), has been expanded to metaplasia of peritoneal stem cells (215, 221–231), endometrial stem cells (232, 233), and more recently bone marrow cells (221, 225, 234–238), pale cells (239, 240) and embryonic remnants (241–243). These concepts find support in the frequent mesothelial-mesenchymal transitions with a role of platelets (244) and in the role of bone marrow cells in peritoneal repair (245). Metaplasia, unfortunately, is a poorly defined concept. If metaplasia is defined as metaplastic changes without permanent and transmissible genetic or epigenetic changes, the resulting endometriosis cells are genetically and epigenetically similar to endometrium and lesions after retrograde menstruation and implantation. If, on the contrary, metaplasia indicates stable and transmissible genetic or epigenetic changes, this comes close to the genetic/epigenetic theory.

### The Genetic/Epigenetic Theory

The endometriotic disease theory (EDT) postulated (246) that genetic incidents are required for the development of typical,



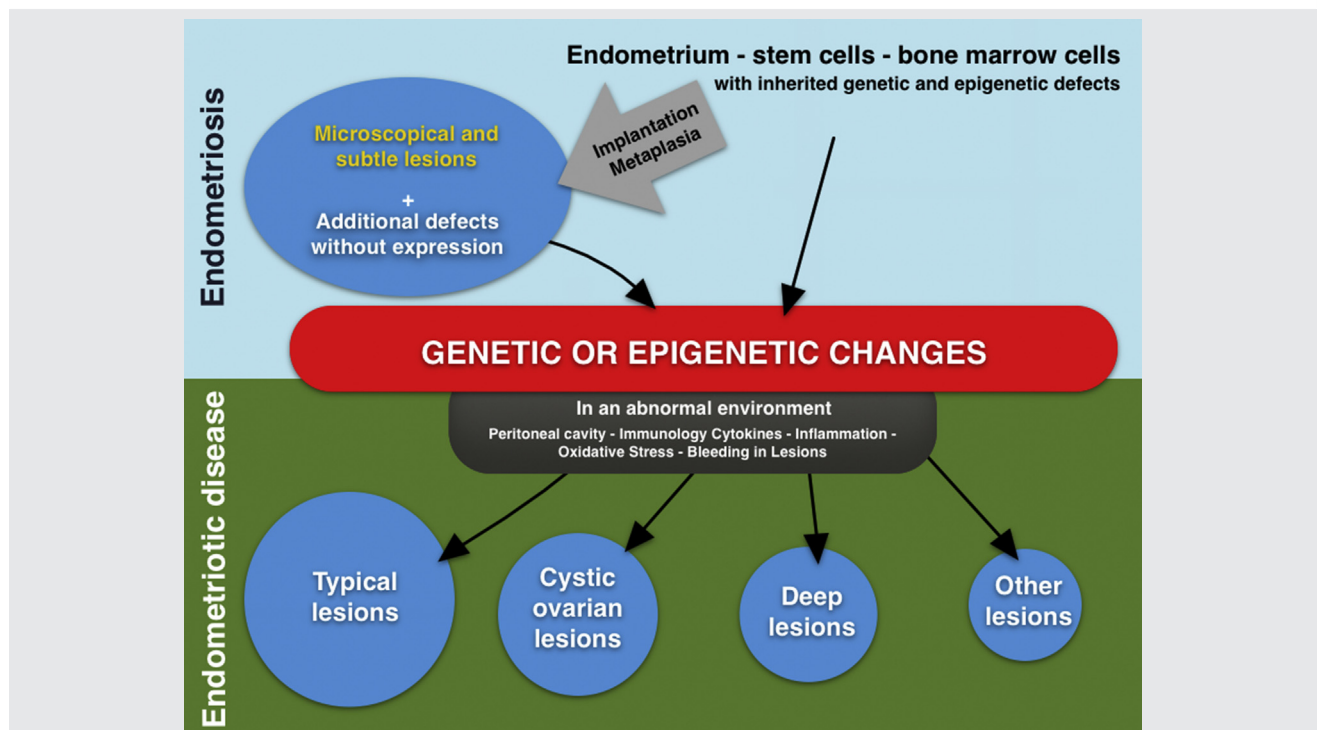
cystic, or deep endometriosis. Microscopic and subtle endometriosis were considered to be early lesions following implantation of endometrium occurring intermittently in all women (247). It was suggested to use “endometriosis” for these “normal” subtle endometriosis cells and “endometriotic disease” for lesions with genetically abnormal cells and clinical symptoms. The development into typical, cystic, or deep lesions was postulated to be the consequence of the type of genetic incidents. Some subtle lesions thus contain “normal” cells that would regress spontaneously, whereas others would progress to more severe disease (20).

The genetic/epigenetic theory (Fig. 2) is an update of the EDT by adding current knowledge of genetic and epigenetic changes and of the redundancy of cellular processes. First, the oxidative stress in the uterus during menstruation and in the peritoneal cavity following retrograde menstruation (248) are recognized as potential causative factors to induce genetic or epigenetic changes. In addition, we recently realized the association of endometriosis with vaginal and pelvic infection (78, 136, 138) and the presence of an important metabolome in the uterine and peritoneal cavities. Second, functional redundancy is a characteristic of many cellular processes. Redundancy means that a similar task can be achieved by several pathways, albeit not with the same efficiency. They can take longer, and the capacity can be

less. Redundant mechanisms explain the cumulative effect of sequential genetic and epigenetic incidents. They also can mask the (phenotypic) effect of genetic and epigenetic changes (249). They explain that effects become visible only when a higher capacity is needed. Today, we can only speculate what combination of and how genetic and epigenetic incidents lead to typical, cystic, or deep or extragenital forms of endometriosis.

The genetic/epigenetic theory is compatible with all observations made on endometriosis. Subtle or microscopic lesions will progress to more severe lesions only if additional incidents happen. The clinical suggestion that typical, cystic, and deep endometriosis are three different diseases seems logical. It is compatible with hereditary aspects and with a predisposition to develop endometriosis, and it explains why dioxin and total body radiation could increase the risk of endometriosis. It is also compatible with the observation that typical, deep and cystic ovarian endometriosis are clonal in origin, with the clinical heterogeneity of endometriosis lesions, and with the molecular changes observed in endometriosis lesions as well as with the observed genetic and epigenetic aspects (49). The many molecular abnormalities in the endometrium of women with endometriosis are explained as an expression of the genetic and epigenetic changes transmitted at birth. Also, the increased risk of

**FIGURE 2**



The genetic/epigenetic theory. The original cell can be an endometrial cell, a stem cell, or a bone marrow cell with their inherited genetic and epigenetic defects. These defects, together with additional acquired defects without expression constitute the predisposition. After implantation or metaplasia, defined as stable and transmittable changes, subtle and microscopic lesions occur. Additional genetic or epigenetic changes are required for these cells to change behavior and to progress into typical, cystic, deep, or other lesions.

Koninckx. Pathogenesis of endometriosis. Fertil Steril 2018.

pregnancy complications, the associated infertility, and some immunologic alterations could be viewed as the expression of these changes inherited at birth. Even subtle lesions can be viewed as the expression of inherited changes in an abnormal environment.

It should be stressed that this view does not exclude that some associations are the consequence of endometriosis. The final incidents starting the disease are additive to other incidents that might have occurred previously. It can explain the high prevalence in the peritoneal cavity and the increasing prevalence with increased retrograde menstruation. Bleeding and remodeling in the endometriosis lesions (250) are candidates to trigger additional genetic or epigenetic incidents. That many of the molecular biologic alterations described in endometriosis lesions are increasingly viewed as the result of genetic and epigenetic incidents lends further support to the hypothesis.

Some observations are more difficult to explain although they remain compatible. The induction of deep endometriosis-like lesions that develop in baboons by transplantation of functional and basal endometrium together with myometrium and JZ cells (251) is intriguing. First, it is unclear whether baboons are a useful model, because deep endometriosis has not been observed in nonhuman primates except after dioxin administration (252); second, it is unlikely that intact blocks of myometrium and JZ/myometrium are the cause of deep endometriosis in humans. Also intriguing is the role of the increased nerve density and their modulation over time (253, 254). This interaction with the body can be understood as both a cause and a consequence.

The genetic/epigenetic theory has several clinical implications. First, most subtle or microscopic lesions are normal endometrium-like cells that would likely resolve. Typical, cystic, and deep lesions are benign tumors, which after an initial period of rapid growth stop growing or progress slowly and which do not recur after complete excision. However, new lesions can be formed after new incidents, and the probability that this happens increases with the cumulative genetic and epigenetic abnormalities transmitted at birth and acquired throughout life. Adolescent endometriosis becomes a genetic and epigenetic incident early in life, possibly beginning as early as neonatal retrograde menstruation or during fetal life (191).

The genetic and epigenetic defects transmitted at birth explain the predisposition according to the first hit-second hit hypothesis (255) in oncology. However, these defects might also explain the associated subfertility, with monthly fecundity rates below 10% being similar to women with unexplained infertility, the associated changes in the endometrium, and the associated pregnancy problems. The latter is supported by the observation that pregnancy problems do not improve after deep endometriosis excision (256).

The genetic/epigenetic theory explains that with their specific set of changes, endometriotic lesions may vary in their reaction to estrogens, progestins, and pregnancy. The clinical consequence is that lesions vary, that occasional lesions can be rapidly progressive, and that the effect of medical therapy can be variable between patients. Incidents also occur in lesions, and a clonal origin does not exclude heterogeneity

within a lesion as demonstrated for breast (257) and other (258, 259) cancers.

The genetic/epigenetic theory makes it conceivable that the fibrosis surrounding deep endometriosis lesions and eventually the outer cell layers might be composed of normal cells with reversible “metaplastic” changes induced by the endometriosis lesion through cell-cell interaction (260). This suggestion is based on the observation that recurrence rates after (often incomplete) excision and after large bowel resections for deep endometriosis are not strikingly different. Clinically, it might become an argument to be less radical during surgery.

A classification of endometriosis should reflect that microscopic, subtle, typical, cystic, deep and extra-genital endometriosis need to be considered as four or more different entities. Also, the pathophysiology of adenomyosis and its relationship with endometriosis can be explained by this genetic/epigenetic concept (74).

Prevention of genetic/epigenetic incidents triggering the disease can be a matter of speculation. However, it seems attractive to postulate that reduction of repetitive stress by retrograde menstruation and microtrauma in the lesions and prevention of pelvic inflammatory diseases may be useful in this regard.

## GROWTH AND MATURATION OF TYPICAL, CYSTIC, AND DEEP ENDOMETRIOSIS LESIONS

The growth and maturation of lesions varies with the set of genetic and epigenetic changes and with the local environment and thus with the many hormones, immune factors, and growth factors in plasma and the peritoneal cavity. As an example, the high glycodelin concentrations in peritoneal fluid might protect early lesions from NK cell attack (261, 262) and could thus facilitate survival.

Recurrent microbleedings in endometriosis lesions during menstruation can be a cause of pain. These bleeding episodes are also repeated tissue injuries, which are believed to play a role in the maturation of endometriosis (263, 264). In addition, they may trigger additional genetic and epigenetic incidents through inflammation and oxidative stress. Interestingly, microtraumas are also observed in the endometrial-myometrial JZ (239), which is consistent with the Archimeta theory (265, 266).

## DISCUSSION

Mistakes in the DNA sequence are chromosomal alterations, and they can occur during cell division or as a consequence of noxious agents. Most DNA mistakes are repaired by the cell, or the cell becomes apoptotic and dies. However, if the cell survives, the changes persist and are transmitted to the next generation of cells. Activation and repression of DNA transcription and the subsequent translation is a complex process. Stable structural changes in these regulatory mechanisms are called epigenetics (267). Unfortunately, different investigators use different definitions (268). Some, such as the National Institutes of Health Epigenomics Mapping Consortium (269), use the term epigenetics to indicate changes in gene expression; others use it to refer to transgenerational

effects and inherited expression (270). We use epigenetics to indicate stable and transmissible non-DNA changes.

Many words in the endometriosis literature are not clear. This confusion stems from the fact that the meanings of words often change over time, especially after new clinical and molecular-biologic observations are added to the initial clinical, macroscopic, and microscopic descriptions. Stem cell research demonstrated that changes during cellular differentiation can be stable and transmitted, though reversible. It is unclear whether “metaplastic” changes preceding the development of cancer are reversible or whether they signal stable changes that increase the risk that another incident will start the development of a malignant tumor. Metaplasia was introduced as a descriptive histologic observation. A better interpretation of metaplasia is that the underlying mechanisms can be reversible or irreversible changes, and both can be transmitted. The term metaplasia is thus used to indicate the (reversible) expression of environmental stress (271) as well as to indicate the expression of stable genetic or epigenetic damage. Epigenetics describes both reversible and stable changes that are transmitted after cleavage. When transmitted at birth, they are called the epigenetic trait (272).

The implantation theory (1, 11, 201) was a reasonable hypothesis when formulated, while the metaplasia theory (31) was a histologic observation that did not consider genetic or epigenetic changes. The poor definition of metaplasia continues to create confusion. The polygenetic/polyepigenetic theory is compatible with observations made up to now. However, it will remain a theory until disproven by new observations. Understanding the genetic or epigenetic incidents involved, the hereditary incidents, and the environmental factors will be important for prevention, diagnosis, and therapy.

Redundancy of biologic processes adds to the difficulty of identifying minor changes that remain without visible clinical effects. Similar to concepts of tumor biology, it is important to distinguish between hereditary changes transmitted between generations and additional local cellular incidents that would either express the disease or facilitate the expression of the disease after additional incidents later. This distinction is especially important when considering the floating mesothelial and stem cells in peritoneal fluid: A first “facilitating” incident together with predisposition could explain the subsequent development of various forms of endometriosis in different locations (273, 274). This might also explain that deep, peritoneal, and ovarian endometriosis often occur simultaneously in the same individual (275). It is suggested that the same mechanisms apply to adenomyosis.

Similarly to uterine myomas, endometriosis lesions can remain dormant without progression for longer periods of time. Although the mechanisms of reactivation are not understood, deep endometriosis seems to be reactivated by trauma, such as by in vitro fertilization–related needle punctures for oocyte pick-up, triggering the subsequent development of more severe lesions and even a frozen pelvis (56), as frequently observed.

The genetic/epigenetic theory is also important for our views on nonhuman models of induced endometriosis in both primates and rodents. These models remain valid to

study the effect of abnormal environments on (normal) endometrium. Transplantation of human endometriosis into SCID/nude mice could be a model to study the development of (abnormal) endometriotic tissue in a normal or controlled environment.

In conclusion, the genetic/epigenetic theory permits us to explain and understand all observations of this enigmatic disease called endometriosis from heredity and clonality to inflammation, mutations, progesterone resistance, aromatase, and many other findings associated with the disease by the time typical, deep, or cystic endometriosis has developed. Elucidating the mechanisms and pathways involved will hopefully permit the development of more specific means of prevention and therapy of this common and ravaging disease.

**Acknowledgments:** The authors thank Rodrigo Fernandes, Sao Paulo, Brazil, for his help with designing Figure 2; and Jörg Keckstein, Jacques Donnez, and Antonio Setubal for the personal communications concerning the clinical progression of deep endometriosis.

## REFERENCES

1. Sampson JA. Peritoneal endometriosis due to the menstrual dissemination of endometrial tissue into the peritoneal cavity. *Am J Obstet Gynecol* 1927; 14:422–69.
2. Sampson JA. Metastatic or embolic endometriosis, due to the menstrual dissemination of endometrial tissue into the venous circulation. *Am J Pathol* 1927;3:93–110.43.
3. Rokitansky C. Über Uterusdrüsen-Neubildung in Uterus- und Ovarial-Sarcomen [On the neoplasm of uterus glands on uterine and ovarian sarcomas]. *Zeitschr Ges Aerzte Wien* 1860;16:577–81.
4. Cullen TS. Adeno-myoma of the round ligament. *Johns Hopkins Hosp Bull* 1896;7:112–4.
5. Cullen TS. Adenoma-myoma uteri diffusum benignum. *J Hopkins Hosp Bull* 1896;6:133–7.
6. Cullen TS. The distribution of adenomyomata containing uterine mucosa. *Am J Obstet Gynecol* 1919;80:130–8.
7. Lockyer C. Adenomyoma in the recto-uterine and recto-vaginal septa. *Proc R Soc Med* 1913;6:112–20.
8. Sampson JA. Perforating hemorrhagic (chocolate) cysts of the ovary. Their importance and especially their relation to pelvic adenomas of the endometrial type. *Arch Surg* 1921;3:245–323.
9. Hughesdon PE. The endometrial identity of benign stromatosis of the ovary and its relation to other forms of endometriosis. *J Pathol* 1976;119:201–9.
10. Batt RE, Smith RA, Buck Louis GM, Martin DC, Chapron C, Koninckx PR, et al. Mullerianosis. *Histol Histopathol* 2007;22:1161–6.
11. Sampson JA. Benign and malignant endometrial implants in the peritoneal cavity, and their relation to certain ovarian tumors. *Surg Gynecol Obstet* 1924;38:287–311.
12. Fallon J, Brosnan JT, Manning JJ, Moran WG, Meyers J, Fletcher ME. Endometriosis: a report of 400 cases. *R I Med J* 1950;33.
13. Karnaky KJ. Theories and known observations about hormonal treatment of endometriosis-in-situ, and endometriosis at the enzyme level. *Ariz Med* 1969;1:37–41.
14. Goldstein DP, DeCholnoky C, Emans SJ, Leventhal JM. Laparoscopy in the diagnosis and management of pelvic pain in adolescents. *J Reprod Med* 1980;24:251–6.
15. Jansen RPS, Russel P. Nonpigmented endometriosis: clinical, laparoscopic, and pathologic definition. *Am J Obstet Gynecol* 1986;155:1154–9.
16. Koninckx PR, Ide P, Vandenbroucke W, Brosens IA. New aspects of the pathophysiology of endometriosis and associated infertility. *J Reprod Med* 1980;24:257–60.

17. Halme J, Hammond MG, Hulka JF, Raj SG, Talbert LM. Retrograde menstruation in healthy women and in patients with endometriosis. *Obstet Gynecol* 1984;64:151–4.
18. Stripling MC, Martin DC, Chatman DL, Vander Zwaag R, Poston WM. Subtle appearance of pelvic endometriosis. *Fertil Steril* 1988;49:427–31.
19. Martin DC, Hubert GD, Vander Zwaag R, El-Zeky FA. Laparoscopic appearances of peritoneal endometriosis. *Fertil Steril* 1989;51:63–7.
20. Koninckx PR, Donnez J, Brosens I. Microscopic endometriosis: impact on our understanding of the disease and its surgery. *Fertil Steril* 2016;105:305–6.
21. Cornillie FJ, Oosterlynck D, Lauweryns JM, Koninckx PR. Deeply infiltrating pelvic endometriosis: histology and clinical significance. *Fertil Steril* 1990;53:978–83.
22. Anaf V, Simon P, El Nakadi I, Fayt I, Simonart T, Buxant F, et al. Hyperalgesia, nerve infiltration and nerve growth factor expression in deep adenomyotic nodules, peritoneal and ovarian endometriosis. *Hum Reprod* 2002;17:1895–900.
23. Siquara de Sousa AC, Capek S, Amrami KK, Spinner RJ. Neural involvement in endometriosis: review of anatomic distribution and mechanisms. *Clin Anat* 2015;28:1029–38.
24. Anaf V, El Nakadi I, Simon P, van de Stadt J, Fayt I, Simonart T, et al. Preferential infiltration of large bowel endometriosis along the nerves of the colon. *Hum Reprod* 2004;19:996–1002.
25. Mechsner S, Weichbrodt M, Riedlinger WF, Bartley J, Kaufmann AM, Schneider A, et al. Estrogen and progesterone receptor positive endometriotic lesions and disseminated cells in pelvic sentinel lymph nodes of patients with deep infiltrating rectovaginal endometriosis: a pilot study. *Hum Reprod* 2008;23:2202–9.
26. Jerman LF, Hey-Cunningham AJ. The role of the lymphatic system in endometriosis: a comprehensive review of the literature. *Biol Reprod* 2015;92:64.
27. Koninckx PR, Meuleman C, Demeyere S, Lesaffre E, Cornillie FJ. Suggestive evidence that pelvic endometriosis is a progressive disease, whereas deeply infiltrating endometriosis is associated with pelvic pain. *Fertil Steril* 1991;55:759–65.
28. Koninckx PR, Martin DC. Deep endometriosis: a consequence of infiltration or retraction or possibly adenomyosis externa? *Fertil Steril* 1992;58:924–8.
29. Koninckx PR, Heyns W, Verhoeven G, van Baelen H, Lissens WD, de Moor P, et al. Biochemical characterization of peritoneal fluid in women during the menstrual cycle. *J Clin Endocrinol Metab* 1980;51:1239–44.
30. Kawano Y, Hirakawa T, Nishida M, Yuge A, Yano M, Nasu K, et al. Functioning endometrium and endometrioma in a patient with Mayer-Rokitanski-Kuster-Hauser syndrome. *Jpn Clin Med* 2014;5:43–5.
31. Gruenewald P. Origin of endometriosis from the mesenchyme of the celomic walls. *Am J Obstet Gynecol* 1942;44:470–4.
32. Giannarini G, Scott CA, Moro U, Grossetti B, Pomara G, Selli C. Cystic endometriosis of the epididymis. *Urology* 2006;68:203.
33. Jabr FI, Mani V. An unusual cause of abdominal pain in a male patient: endometriosis. *Avicenna J Med* 2014;4:99–101.
34. Simpson JL, Elias S, Malinak LR, Buttram VCJ. Heritable aspects of endometriosis. I. Genetic studies. *Am J Obstet Gynecol* 1980;137:327–31.
35. Coxhead D, Thomas EJ. Familial inheritance of endometriosis in a British population. A case control study. *J Obstet Gynecol* 1993;13:42–4.
36. Kennedy S. The genetics of endometriosis. *J Reprod Med* 1998;43:263–8.
37. Kennedy S, Hadfield R, Westbrook C, Weeks DE, Barlow D, Golding S. Magnetic resonance imaging to assess familial risk in relatives of women with endometriosis. *Lancet* 1998;352:1440–1.
38. Kennedy SH, Mardon H, Barlow DH. Familial endometriosis. *J Assist Reprod Genet* 1995;12:32–4.
39. Hadfield RM, Yudkin PL, Coe CL, Scheffler J, Uno H, Barlow DH, et al. Risk factors for endometriosis in the rhesus monkey (*Macaca mulatta*): a case-control study. *Hum Reprod Update* 1997;3:109–15.
40. Hadfield RM, Mardon HJ, Barlow DH, Kennedy SH. Endometriosis in monozygotic twins. *Fertil Steril* 1997;68:941–2.
41. Moen MH, Magnus P. The familial risk of endometriosis. *Acta Obstet Gynecol Scand* 1993;72:560–4.
42. Moen MH. Endometriosis in monozygotic twins. *Acta Obstet Gynecol Scand* 1994;73:59–62.
43. Treloar SA, O'Connor DT, O'Connor VM, Martin NG. Genetic influences on endometriosis in an Australian twin sample. *Fertil Steril* 1999;71:701–10.
44. Kennedy S, Hadfield R, Mardon H, Barlow D. Age of onset of pain symptoms in nontwin sisters concordant for endometriosis. *Hum Reprod* 1996;11:403–5.
45. Sapkota Y, Attia J, Gordon SD, Henders AK, Holliday EG, Rahmioglu N, et al. Genetic burden associated with varying degrees of disease severity in endometriosis. *Mol Hum Reprod* 2015;21:594–602.
46. Saha R, Pettersson HJ, Svedberg P, Olovsson M, Bergqvist A, Marions L, et al. The heritability of endometriosis. *Fertil Steril* 2015;104:947–52.
47. Baranov VS, Ivaschenko TE, Liehr T, Yarmolinskaya MI. Systems genetics view of endometriosis: a common complex disorder. *Eur J Obstet Gynecol Reprod Biol* 2015;185:59–65.
48. Agrawal S, Tapmeier T, Rahmioglu N, Kirtley S, Zondervan K, Becker C. The miRNA mirage: how close are we to finding a non-invasive diagnostic biomarker in endometriosis? A systematic review. *Int J Mol Sci* 2018;19.
49. Borghese B, Zondervan KT, Abrao MS, Chapron C, Vaiman D. Recent insights on the genetics and epigenetics of endometriosis. *Clin Genet* 2017;91:254–64.
50. Rahmioglu N, Macgregor S, Drong AW, Hedman AK, Harris HR, Randall JC, et al. Genome-wide enrichment analysis between endometriosis and obesity-related traits reveals novel susceptibility loci. *Hum Mol Genet* 2015;24:1185–99.
51. Fung JN, Montgomery GW. Genetics of endometriosis: state of the art on genetic risk factors for endometriosis. *Best Pract Res Clin Obstet Gynaecol* 2018;50:61–71.
52. Matalliotakis M, Zervou MI, Matalliotaki C, Rahmioglu N, Koumantakis G, Kalogiannidis I, et al. The role of gene polymorphisms in endometriosis. *Mol Med Rep* 2017;16:5881–6.
53. Zondervan KT, Rahmioglu N, Morris AP, Nyholt DR, Montgomery GW, Becker CM, et al. Beyond endometriosis genome-wide association study: from genomics to phenomics to the patient. *Semin Reprod Med* 2016;34:242–54.
54. Sapkota Y, Steinhorsdottir V, Morris AP, Fassbender A, Rahmioglu N, de Vivo I, et al. Meta-analysis identifies five novel loci associated with endometriosis highlighting key genes involved in hormone metabolism. *Nat Commun* 2017;8:15539.
55. Guo SW. The association of endometriosis risk and genetic polymorphisms involving dioxin detoxification enzymes: a systematic review. *Eur J Obstet Gynecol Reprod Biol* 2006;124:134–43.
56. Canis M, Bourdel N, Houle C, Gremeau AS, Botchorishvili R, Matsuzaki S. Endometriosis may not be a chronic disease: an alternative theory offering more optimistic prospects for our patients. *Fertil Steril* 2016;105:32–4.
57. Evers JL. Is adolescent endometriosis a progressive disease that needs to be diagnosed and treated? *Hum Reprod* 2013;28:2023.
58. Koninckx PR, Ussia A, Keckstein J, Wattiez A, Adamyan L. Epidemiology of subtle, typical, cystic, and deep endometriosis: a systematic review. *Gynaecol Surg* 2016;13:457–67.
59. Guo SW. Recurrence of endometriosis and its control. *Hum Reprod Update* 2009;15:141–61.
60. Ianieri MM, Mautone D, Ceccaroni M. Recurrence in deep infiltrating endometriosis: a systematic review of the literature. *J Minim Invasive Gynecol* 2018;25:786–93.
61. Busacca M, Marana R, Caruana P, Candiani M, Muzii L, Calia C, et al. Recurrence of ovarian endometrioma after laparoscopic excision. *Am J Obstet Gynecol* 1999;180:519–23.
62. Moscarini M, Milazzo GN, Assorgi C, Pacchiarotti A, Caserta D. Ovarian stripping versus cystectomy: recurrence of endometriosis and pregnancy rate. *Arch Gynecol Obstet* 2014;290:163–7.
63. Muzii L, Miller CE. The singer, not the song. *J Minim Invasive Gynecol* 2011;18:666–7.
64. Missmer SA, Cramer DW. The epidemiology of endometriosis. *Obstet Gynecol Clin North Am* 2003;30:1–19.



65. Koninckx PR, Meuleman C, Oosterlynck D, Cornillie FJ. Diagnosis of deep endometriosis by clinical examination during menstruation and plasma CA-125 concentration. *Fertil Steril* 1996;65:280–7.
66. Setubal A, Sidiropoulou Z, Torgal M, Casal E, Lourenco C, Koninckx P. Bowel complications of deep endometriosis during pregnancy or in vitro fertilization. *Fertil Steril* 2014;101:442–6.
67. Vigano P, Corti L, Berlanda N. Beyond infertility: obstetrical and postpartum complications associated with endometriosis and adenomyosis. *Fertil Steril* 2015;104:802–12.
68. Kalu E, Richardson R, Sellu D, Kubba F. Endometriosis-associated ileo-cecal perforation in a woman on the pseudopregnancy regimen. *J Minim Invasive Gynecol* 2008;15:764–6.
69. Lambrechts S, van Calsteren K, Capoen A, op de Beeck K, Joniau S, Timmerman D, et al. A case of polypoid endometriosis of the bladder during pregnancy mimicking urachal carcinoma. *Ultrasound Obstet Gynecol* 2011;38:475–8.
70. Maggiore U, Remorgida V, Sala P, Vellone VG, Biscaldi E, Ferrero S. Spontaneous uroperitoneum and preterm delivery in a patient with bladder endometriosis. *J Minim Invasive Gynecol* 2015;22:923–4.
71. Brosens IA, Lier MC, Mijatovic V, Habiba M, Benagiano G. Severe spontaneous hemoperitoneum in pregnancy may be linked to in vitro fertilization in patients with endometriosis: a systematic review. *Fertil Steril* 2016;106:692–703.
72. Asencio FA, Ribeiro HA, Ribeiro PA, Mario M, Adamyan L, Ussia A, et al. Case reports and systematic review of estrogen independent symptomatic postmenopausal endometriosis. *Gynecol Surgery* 2018. In press.
73. Koninckx PR, Ussia A, Adamyan L, Wattiez A, Donnez J. Deep endometriosis: definition, diagnosis, and treatment. *Fertil Steril* 2012;98:564–71.
74. Koninckx PR, Ussia A, Zupi E, Gomel V. Association of endometriosis and adenomyosis: vast literature but scant conclusive data. *J Minim Invasive Gynecol* 2018;25:745–8.
75. Chapron C, Tosti C, Marcellin L, Bourdon M, Lafay-Pillet MC, Millischer AE, et al. Relationship between the magnetic resonance imaging appearance of adenomyosis and endometriosis phenotypes. *Hum Reprod* 2017;32:1393–401.
76. di Donato N, Montanari G, Benfenati A, Leonardi D, Bertoldo V, Monti G, et al. Prevalence of adenomyosis in women undergoing surgery for endometriosis. *Eur J Obstet Gynecol Reprod Biol* 2014;181:289–93.
77. Olovsson M. Immunological aspects of endometriosis: an update. *Am J Reprod Immunol* 2011;66(Suppl 1):101–4.
78. Kobayashi H, Higashiura Y, Shigetomi H, Kajihara H. Pathogenesis of endometriosis: the role of initial infection and subsequent sterile inflammation [review]. *Mol Med Rep* 2014;9:9–15.
79. Kralickova M, Vetrovicka V. Immunological aspects of endometriosis: a review. *Ann Transl Med* 2015;3:153.
80. Thiruchelvam U, Wingfield M, O'Farrelly C. Natural killer cells: key players in endometriosis. *Am J Reprod Immunol* 2015;74:291–301.
81. Parkin KL, Fazleabas AT. Uterine leukocyte function and dysfunction: a hypothesis on the impact of endometriosis. *Am J Reprod Immunol* 2016;75:411–7.
82. de Barros IBL, Malvezzi H, Gueuvoghlian-Silva BY, Piccinato CA, Rizzo LV, Podgaec S. What do we know about regulatory T cells and endometriosis? A systematic review. *J Reprod Immunol* 2017;120:48–55.
83. Sikora J, Smycz-Kubanska M, Mielczarek-Palacz A, Kondera-Anasz Z. Abnormal peritoneal regulation of chemokine activation—the role of IL-8 in pathogenesis of endometriosis. *Am J Reprod Immunol* 2017;77.
84. Ahn SH, Monsanto SP, Miller C, Singh SS, Thomas R, Tayade C. Pathophysiology and immune dysfunction in endometriosis. *Biomed Res Int* 2015;2015:795976.
85. Riccio L, Santulli P, Marcellin L, Abrao MS, Batteux F, Chapron C. Immunology of endometriosis. *Best Pract Res Clin Obstet Gynaecol* 2018;50:39–49.
86. Takamura M, Koga K, Izumi G, Hirata T, Harada M, Hirota Y, et al. Simultaneous detection and evaluation of four subsets of CD4+ T lymphocyte in lesions and peripheral blood in endometriosis. *Am J Reprod Immunol* 2015;74:480–6.
87. Sinreih M, Anko M, Kene NH, Kocbek V, Rizner TL. Expression of AKR1B1, AKR1C3 and other genes of prostaglandin F2 $\alpha$  biosynthesis and action in ovarian endometriosis tissue and in model cell lines. *Chem Biol Interact* 2015;234:320–31.
88. Mu F, Hankinson SE, Schernhammer E, Pollak MN, Missmer SA. A prospective study of insulin-like growth factor 1, its binding protein 3, and risk of endometriosis. *Am J Epidemiol* 2015;182:148–56.
89. Oosterlynck DJ, Meuleman C, Waer M, Koninckx PR. CO<sub>2</sub>-laser excision of endometriosis does not improve the decreased natural killer activity. *Acta Obstet Gynecol Scand* 1994;73:333–7.
90. Halme J, White C, Kauma S, Estes J, Haskill S. Peritoneal macrophages from patients with endometriosis release growth factor activity in vitro. *J Clin Endocrinol Metab* 1988;66:1044–9.
91. Koninckx PR, Kennedy SH, Barlow DH. Endometriotic disease: the role of peritoneal fluid. *Hum Reprod Update* 1998;4:741–51.
92. Barcz E, Kaminski P, Marianowski L. Role of cytokines in pathogenesis of endometriosis. *Med Sci Monit* 2000;6:1042–6.
93. Harada T, Iwabe T, Terakawa N. Role of cytokines in endometriosis. *Fertil Steril* 2001;76:1–10.
94. Wu MY, Ho HN. The role of cytokines in endometriosis. *Am J Reprod Immunol* 2003;49:285–96.
95. Kyama CM, Mihalyi A, Simsa P, Falconer H, Fulop V, Mwenda JM, et al. Role of cytokines in the endometrial-peritoneal cross-talk and development of endometriosis. *Front Biosci (Elite Ed)* 2009;1:444–54.
96. Vouk K, Ribic-Pucelj M, Adamski J, Rizner TL. Altered levels of acylcarnitines, phosphatidylcholines, and sphingomyelins in peritoneal fluid from ovarian endometriosis patients. *J Steroid Biochem Mol Biol* 2016;159:60–9.
97. Liu XJ, Bai XG, Teng YL, Song L, Lu N, Yang RQ. miRNA-15a-5p regulates VEGFA in endometrial mesenchymal stem cells and contributes to the pathogenesis of endometriosis. *Eur Rev Med Pharmacol Sci* 2016;20:3319–26.
98. Young VJ, Ahmad SF, Brown JK, Duncan WC, Horne AW. Peritoneal VEGF-A expression is regulated by TGF- $\beta$ 1 through an ID1 pathway in women with endometriosis. *Sci Rep* 2015;5:16859.
99. Oosterlynck DJ, Meuleman C, Sobis H, Vandeputte M, Koninckx PR. Angiogenic activity of peritoneal fluid from women with endometriosis. *Fertil Steril* 1993;59:778–82.
100. Morgan KG, Wilkinson N, Buckley CH. Angiogenesis in normal, hyperplastic, and neoplastic endometrium. *J Pathol* 1996;179:317–20.
101. Taylor RN, Ryan IP, Moore ES, Hornung D, Shifren JL, Tseng JF. Angiogenesis and macrophage activation in endometriosis. Bulletti C, deZiegler D, Guller S, Levitz M, editors. *Uterus: endometrium and myometrium*, 828. New York: New York Academy Sciences; 1997:194–207.
102. Healy DL, Rogers PA, Hii L, Wingfield M. Angiogenesis: a new theory for endometriosis. *Hum Reprod Update* 1998;4:736–40.
103. Matsuzaki S, Canis M, Darcha C, Dechelotte P, Pouly JL, Bruhat MA. Angiogenesis in endometriosis. *Gynecol Obstet Invest* 1998;46:111–5.
104. Fujimoto J, Sakaguchi H, Hirose R, Wen H, Tamaya T. Angiogenesis in endometriosis and angiogenic factors. *Gynecol Obstet Invest* 1999;48(Suppl 1):14–20.
105. Gazvani R, Templeton A. Peritoneal environment, cytokines and angiogenesis in the pathophysiology of endometriosis. *Reproduction* 2002;123:217–26.
106. Taylor RN, Lebovic DI, Mueller MD. Angiogenic factors in endometriosis. *Ann N Y Acad Sci* 2002;955:89–100.
107. Becker CM, d'Amato RJ. Angiogenesis and antiangiogenic therapy in endometriosis. *Microvasc Res* 2007;74:121–30.
108. Laschke MW, Menger MD. In vitro and in vivo approaches to study angiogenesis in the pathophysiology and therapy of endometriosis. *Hum Reprod Update* 2007;13:331–42.
109. May K, Becker CM. Endometriosis and angiogenesis. *Minerva Ginecol* 2008;60:245–54.
110. Van LA, Donnez J, Defrere S, Dunselman GA, Groothuis PG. Antiangiogenic and vascular-disrupting agents in endometriosis: pitfalls and promises. *Mol Hum Reprod* 2008;14:259–68.

111. Rogers PA, Donoghue JF, Walter LM, Girling JE. Endometrial angiogenesis, vascular maturation, and lymphangiogenesis. *Reprod Sci* 2009;16:147–51.
112. Taylor RN, Yu J, Torres PB, Schickedanz AC, Park JK, Mueller MD, et al. Mechanistic and therapeutic implications of angiogenesis in endometriosis. *Reprod Sci* 2009;16:140–6.
113. Laschke MW, Menger MD. Antiangiogenic treatment strategies for the therapy of endometriosis. *Hum Reprod Update* 2012;18:682–702.
114. Machado-Linde F, Pelegrin P, Sanchez-Ferrer ML, Leon J, Cascales P, Parrilla JJ. 2-Methoxyestradiol in the pathophysiology of endometriosis: focus on angiogenesis and therapeutic potential. *Reprod Sci* 2012;19:1018–29.
115. Hey-Cunningham AJ, Peters KM, Zevallos HB, Berbic M, Markham R, Fraser IS. Angiogenesis, lymphangiogenesis and neurogenesis in endometriosis. *Front Biosci (Elite Ed)* 2013;5:1033–56.
116. Djokovic D, Calhaz-Jorge C. Angiogenesis as a therapeutic target in endometriosis. *Acta Med Port* 2014;27:489–97.
117. Mari-Alexandre J, Garcia-Oms J, Barcelo-Molina M, Gilabert-Aguilar J, Estelles A, Braza-Boils A, et al. MicroRNAs and angiogenesis in endometriosis. *Thromb Res* 2015;135(Suppl 1):S38–40.
118. Gogacz M, Galczynski K, Romanek-Piva K, Winkler I, Rechberger T, Adamiak-Godlewska A. [Concentration of selected angiogenic factors in serum and peritoneal fluid of women with endometriosis]. *Ginekol Pol* 2015;86:188–92.
119. Dela CC, Reis FM. The role of TGF $\beta$  superfamily members in the pathophysiology of endometriosis. *Gynecol Endocrinol* 2015;31:511–5.
120. Koninckx PR, Riittinen L, Seppala M, Cornillie FJ. CA-125 and placental protein 14 concentrations in plasma and peritoneal fluid of women with deeply infiltrating pelvic endometriosis. *Fertil Steril* 1992;57:523–30.
121. Barbieri RL. Stenosis of the external cervical os: an association with endometriosis in women with chronic pelvic pain. *Fertil Steril* 1998;70:571–3.
122. Koninckx PR, Gomel V. Introduction: Quality of pelvic surgery and postoperative adhesions. *Fertil Steril* 2016;106:991–3.
123. Koninckx PR, Gomel V, Ussia A, Adamyan L. Role of the peritoneal cavity in the prevention of postoperative adhesions, pain, and fatigue. *Fertil Steril* 2016;106:998–1010.
124. Carvalho L, Podgaec S, Bellodi-Privato M, Falcone T, Abrao MS. Role of eutopic endometrium in pelvic endometriosis. *J Minim Invasive Gynecol* 2011;18:419–27.
125. Lessey BA, Lebovic DI, Taylor RN. Eutopic endometrium in women with endometriosis: ground zero for the study of implantation defects. *Semin Reprod Med* 2013;31:109–24.
126. Herndon CN, Aghajanova L, Balayan S, Erikson D, Barragan F, Goldfien G, et al. Global transcriptome abnormalities of the eutopic endometrium from women with adenomyosis. *Reprod Sci* 2016;23:1289–303.
127. Lagana AS, Triolo O, Salmeri FM, Granese R, Palmara VI, Ban FH, et al. Natural killer T cell subsets in eutopic and ectopic endometrium: a fresh look to a busy corner. *Arch Gynecol Obstet* 2016;293:941–9.
128. da Costa e Silva Rde C, Moura KK, Ribeiro Junior CL, Guillo LA. Estrogen signaling in the proliferative endometrium: implications in endometriosis. *Rev Assoc Med Bras (1992)* 2016;62:72–7.
129. Mehaseb MK, Bell SC, Pringle JH, Habiba MA. Uterine adenomyosis is associated with ultrastructural features of altered contractility in the inner myometrium. *Fertil Steril* 2010;93:2130–6.
130. Pan ML, Chen LR, Tsao HM, Chen KH. Risk of gestational hypertension-preeclampsia in women with preceding endometriosis: a nationwide population-based study. *PLoS One* 2017;12:e0181261.
131. Koninckx PR, Zupi E, Martin DC. Endometriosis and pregnancy outcome. *Fertil Steril* 2018;110:406–7.
132. Hasdemir PS, Farasat M, Aydin C, Ozyurt BC, Guvenal T, Pekindil G. The role of adenomyosis in the pathogenesis of preeclampsia. *Geburtshilfe Frauenheilkd* 2016;76:882–7.
133. Hashimoto A, Iriyama T, Sayama S, Nakayama T, Komatsu A, Miyauchi A, et al. Adenomyosis and adverse perinatal outcomes: increased risk of second trimester miscarriage, preeclampsia, and placental malposition. *J Matern Fetal Neonatal Med* 2018;31:364–9.
134. Khan KN, Kitajima M, Hiraki K, Yamaguchi N, Katamine S, Matsuyama T, et al. *Escherichia coli* contamination of menstrual blood and effect of bacterial endotoxin on endometriosis. *Fertil Steril* 2010;94:2860–3, e1–3.
135. Khan KN, Fujishita A, Hiraki K, Kitajima M, Nakashima M, Fushiki S, et al. Bacterial contamination hypothesis: a new concept in endometriosis. *Reprod Med Biol* 2018;17:125–33.
136. Lin WC, Chang CY, Hsu YA, Chiang JH, Wan L. Increased risk of endometriosis in patients with lower genital tract infection: a nationwide cohort study. *Medicine (Baltimore)* 2016;95:e2773.
137. Cicinelli E, Trojano G, Mastromauro M, Vimercati A, Marinaccio M, Mitola PC, et al. Higher prevalence of chronic endometritis in women with endometriosis: a possible etiopathogenetic link. *Fertil Steril* 2017;108:289–95.e1.
138. Heidarpour M, Derakhshan M, Derakhshan-Horeh M, Kheirollahi M, Dashti S. Prevalence of high-risk human papillomavirus infection in women with ovarian endometriosis. *J Obstet Gynaecol Res* 2017;43:135–9.
139. Lim MC, Pfaendler K. Type and risk of cancer related to endometriosis: ovarian cancer and beyond. *BJOG* 2018;125:73.
140. Dawson A, Fernandez ML, Anglesio M, Yong PJ, Carey MS. Endometriosis and endometriosis-associated cancers: new insights into the molecular mechanisms of ovarian cancer development. *E Cancermedicallscience* 2018;12:803.
141. Guo SW. Endometriosis and ovarian cancer: potential benefits and harms of screening and risk-reducing surgery. *Fertil Steril* 2015;104:813–30.
142. Koninckx PR. The physiopathology of endometriosis: pollution and dioxin. *Gynecol Obstet Invest* 1999;47(Suppl 1):47–9.
143. Rier S, Foster WG. Environmental dioxins and endometriosis. *Semin Reprod Med* 2003;21:145–54.
144. Guo SW, Simsa P, Kyama CM, Mihalyi A, Fulop V, Othman EE, et al. Reassessing the evidence for the link between dioxin and endometriosis: from molecular biology to clinical epidemiology. *Mol Hum Reprod* 2009;15:609–24.
145. Bruner-Tran KL, Osteen KG. Dioxin-like PCBs and endometriosis. *Syst Biol Reprod Med* 2010;56:132–46.
146. Wood DH, Yochmowitz MG, Salmon YL, Eason RL, Boster RA. Proton irradiation and endometriosis. *Aviat Space Envir Med* 1983;54:718–24.
147. Fanton JW, Golden JG. Radiation-induced endometriosis in *Macaca mulatta*. *Radiat Res* 1991;126:141–6.
148. Sofo V, Gotte M, Lagana AS, Salmeri FM, Triolo O, Sturlese E, et al. Correlation between dioxin and endometriosis: an epigenetic route to unravel the pathogenesis of the disease. *Arch Gynecol Obstet* 2015;292:973–86.
149. Wu Y, Basir Z, Kajdacsy-Balla A, Strawn E, Macias V, Montgomery K, et al. Resolution of clonal origins for endometriotic lesions using laser capture microdissection and the human androgen receptor (HUMARA) assay. *Fertil Steril* 2003;79(Suppl 1):710–7.
150. Mayr D, Amann G, Siefert C, Diebold J, Anderegg B. Does endometriosis really have premalignant potential? A clonal analysis of laser-microdissected tissue. *FASEB J* 2003;17:693–5.
151. Tamura M, Fukaya T, Murakami I, Uehara S, Yajima A. Analysis of clonality in human endometriotic cysts based on evaluation of X chromosome inactivation in archival formalin-fixed, paraffin-embedded tissue. *Lab Invest* 1998;78:213–8.
152. Yano T, Jimbo H, Yoshikawa H, Tsutsumi O, Taketani Y. Molecular analysis of clonality in ovarian endometriotic cysts. *Gynecol Obstet Invest* 1999;47(Suppl 1):41–5.
153. Jimbo H, Hitomi Y, Yoshikawa H, Yano T, Momoeda M, Sakamoto A, et al. Evidence for monoclonal expansion of epithelial cells in ovarian endometriotic cysts. *Am J Pathol* 1997;150:1173–8.
154. Bulun SE, Monsivais D, Kakinuma T, Furukawa Y, Bernardi L, Pavone ME, et al. Molecular biology of endometriosis: from aromatase to genomic abnormalities. *Semin Reprod Med* 2015;33:220–4.
155. Bulun SE, Cheng YH, Yin P, Imir G, Utsunomiya H, Attar E, et al. Progesterone resistance in endometriosis: link to failure to metabolize estradiol. *Mol Cell Endocrinol* 2006;248:94–103.
156. Wang C, Mavrogianis PA, Fazleabas AT. Endometriosis is associated with progesterone resistance in the baboon (*Papio anubis*) oviduct: evidence

- based on the localization of oviductal glycoprotein 1 (OVGP1). *Biol Reprod* 2009;80:272–8.
157. Bruner-Tran KL, Ding T, Osteen KG. Dioxin and endometrial progesterone resistance. *Semin Reprod Med* 2010;28:59–68.
  158. Bulun SE, Cheng YH, Pavone ME, Yin P, Imir G, Utsunomiya H, et al. 17 $\beta$ -Hydroxysteroid dehydrogenase-2 deficiency and progesterone resistance in endometriosis. *Semin Reprod Med* 2010;28:44–50.
  159. Al-Sabbagh M, Lam EW, Brosens JJ. Mechanisms of endometrial progesterone resistance. *Mol Cell Endocrinol* 2012;358:208–15.
  160. Barragan F, Irwin JC, Balayan S, Erikson DW, Chen JC, Houshdaran S, et al. Human endometrial fibroblasts derived from mesenchymal progenitors inherit progesterone resistance and acquire an inflammatory phenotype in the endometrial niche in endometriosis. *Biol Reprod* 2016;94:118.
  161. Joshi NR, Miyadahira EH, Afshar Y, Jeong JW, Young SL, Lessey BA, et al. Progesterone resistance in endometriosis is modulated by the altered expression of microRNA-29c and FKBP4. *J Clin Endocrinol Metab* 2017;102:141–9.
  162. Patel BG, Rudnicki M, Yu J, Shu Y, Taylor RN. Progesterone resistance in endometriosis: origins, consequences and interventions. *Acta Obstet Gynecol Scand* 2017;96:623–32.
  163. Leyendecker G, Herberich M, Kunz G, Mall G. Endometriosis results from the dislocation of basal endometrium. *Hum Reprod* 2002;17:2725–36.
  164. Uimari O, Rahmioglu N, Nyholt DR, Vincent K, Missmer SA, Becker C, et al. Genome-wide genetic analyses highlight mitogen-activated protein kinase (MAPK) signaling in the pathogenesis of endometriosis. *Hum Reprod* 2017;32:780–93.
  165. Kim BG, Yoo JY, Kim TH, Shin JH, Langenheim JF, Ferguson SD, et al. Aberrant activation of signal transducer and activator of transcription-3 (STAT3) signaling in endometriosis. *Hum Reprod* 2015;30:1069–78.
  166. Fung JN, Holdsworth-Carson SJ, Sapkota Y, Zhao ZZ, Jones L, Girling JE, et al. Functional evaluation of genetic variants associated with endometriosis near GREB1. *Hum Reprod* 2015;30:1263–75.
  167. Zanatta A, Rocha AM, Carvalho FM, Pereira RM, Taylor HS, Motta EL, et al. The role of the Hoxa10/HOXA10 gene in the etiology of endometriosis and its related infertility: a review. *J Assist Reprod Genet* 2010;27:701–10.
  168. Rakhila H, Al-Akoum M, Bergeron ME, Leboeuf M, Lemyre M, Akoum A, et al. Promotion of angiogenesis and proliferation cytokines patterns in peritoneal fluid from women with endometriosis. *J Reprod Immunol* 2016;116:1–6.
  169. Sapkota Y, Low SK, Attia J, Gordon SD, Henders AK, Holliday EG, et al. Association between endometriosis and the interleukin 1A (IL1A) locus. *Hum Reprod* 2015;30:239–48.
  170. Malutan AM, Drugan C, Walch K, Drugan T, Ciordea R, Mihu D. The association between interleukin-10 (IL-10) 592C/A, 819T/C, 1082G/A promoter polymorphisms and endometriosis. *Arch Gynecol Obstet* 2017;295:503–10.
  171. Ahn SH, Edwards AK, Singh SS, Young SL, Lessey BA, Tayade C. IL-17A contributes to the pathogenesis of endometriosis by triggering proinflammatory cytokines and angiogenic growth factors. *J Immunol* 2015;195:2591–600.
  172. Izumi G, Koga K, Takamura M, Makabe T, Nagai M, Urata Y, et al. Mannose receptor is highly expressed by peritoneal dendritic cells in endometriosis. *Fertil Steril* 2017;107:167–73.
  173. Ingles SA, Wu L, Liu BT, Chen Y, Wang CY, Templeman C, et al. Differential gene expression by 1,25(OH)<sub>2</sub>D<sub>3</sub> in an endometriosis stromal cell line. *J Steroid Biochem Mol Biol* 2017;173:223–7.
  174. Binda MM, Donnez J, Dolmans MM. Targeting mast cells: a new way to treat endometriosis. *Expert Opin Ther Targets* 2017;21:67–75.
  175. Paula R Jr, Oliani AH, Vaz-Oliani DC, d'Avila SC, Oliani SM, Gil CD. The intricate role of mast cell proteases and the annexin A1–FPR1 system in abdominal wall endometriosis. *J Mol Histol* 2015;46:33–43.
  176. Zhan L, Wang W, Zhang Y, Song E, Fan Y, Wei B. Hypoxia-inducible factor-1 $\alpha$ : A promising therapeutic target in endometriosis. *Biochimie* 2016;123:130–7.
  177. Yun BH, Chon SJ, Choi YS, Cho S, Lee BS, Seo SK. Pathophysiology of endometriosis: role of high mobility group Box-1 and Toll-like receptor 4 developing inflammation in endometrium. *PLoS One* 2016;11:e0148165.
  178. Ye H, He Y, Wang J, Song T, Lan Z, Zhao Y, et al. Effect of matrix metalloproteinase promoter polymorphisms on endometriosis and adenomyosis risk: evidence from a meta-analysis. *J Genet* 2016;95:611–9.
  179. Yang H, Yin J, Ficarrotta K, Hsu SH, Zhang W, Cheng C. Aberrant expression and hormonal regulation of galectin-3 in endometriosis women with infertility. *J Endocrinol Invest* 2016;39:785–91.
  180. Yang H, Liu J, Fan Y, Guo Q, Ge L, Yu N, et al. Associations between various possible promoter polymorphisms of MMPs genes and endometriosis risk: a meta-analysis. *Eur J Obstet Gynecol Reprod Biol* 2016;205:174–88.
  181. Wolfer MM, Kuppers M, Rath W, Buck VU, Meinhold-Heerlein I, Classen-Linke I. Altered expression of progesterone receptor isoforms A and B in human eutopic endometrium in endometriosis patients. *Ann Anat* 2016;206:1–6.
  182. Zhou Y, Zeng C, Li X, Wu PL, Yin L, Yu XL, et al. IGF-1 stimulates ER $\beta$  and aromatase expression via IGF1R/PI3K/AKT-mediated transcriptional activation in endometriosis. *J Mol Med (Berl)* 2016;94:887–97.
  183. Carrarelli P, Yen CF, Arcuri F, Funghi L, Tosti C, Wang TH, et al. Myostatin, follistatin and activin type II receptors are highly expressed in adenomyosis. *Fertil Steril* 2015;104:744–52.
  184. Qu J, Zhu Y, Wu X, Zheng J, Hou Z, Cui Y, et al. Smad3/4 binding to promoter II of P450arom so as to regulate aromatase expression in endometriosis. *Reprod Sci* 2017;24:1187–94.
  185. Goncalves HF, Zendron C, Cavalcante FS, Aiceles V, Oliveira MA, Manaiá JH, et al. Leptin, its receptor and aromatase expression in deep infiltrating endometriosis. *J Ovarian Res* 2015;8:53.
  186. Anglesio MS, Papadopoulos N, Ayhan A, Nazeran TM, Noe M, Horlings HM, et al. Cancer-associated mutations in endometriosis without cancer. *N Engl J Med* 2017;376:1835–48.
  187. Guo SW. Cancer driver mutations in endometriosis: variations on the major theme of fibrogenesis. *Reprod Med Biol* 2018;17:369–97.
  188. Dyson MT, Roqueiro D, Monsivais D, Ercan CM, Pavone ME, Brooks DC, et al. Genome-wide DNA methylation analysis predicts an epigenetic switch for GATA factor expression in endometriosis. *PLoS Genet* 2014;10:e1004158.
  189. Xue Q, Zhou YF, Zhu SN, Bulun SE. Hypermethylation of the CpG island spanning from exon II to intron III is associated with steroidogenic factor 1 expression in stromal cells of endometriosis. *Reprod Sci* 2011;18:1080–4.
  190. Bulun SE. Endometriosis. *N Engl J Med* 2009;360:268–79.
  191. Kobayashi H, Iwai K, Niuro E, Morioka S, Yamada Y. Fetal programming theory: implication for the understanding of endometriosis. *Hum Immunol* 2014;75:208–17.
  192. Guo SW. Epigenetics of endometriosis. *Mol Hum Reprod* 2009;15:587–607.
  193. Houshdaran S, Nezhat CR, Vo KC, Zelenko Z, Irwin JC, Giudice LC. Aberrant endometrial DNA methylome and associated gene expression in women with endometriosis. *Biol Reprod* 2016;95:93.
  194. Zelenko Z, Aghajanova L, Irwin JC, Giudice LC. Nuclear receptor, coregulator signaling, and chromatin remodeling pathways suggest involvement of the epigenome in the steroid hormone response of endometrium and abnormalities in endometriosis. *Reprod Sci* 2012;19:152–62.
  195. Colon-Caraballo M, Monteiro JB, Flores I. H3K27me3 is an epigenetic mark of relevance in endometriosis. *Reprod Sci* 2015;22:1134–42.
  196. Baumann C, Olson M, Wang K, Fazleabas A, de la Fuente R. Arginine methyltransferases mediate an epigenetic ovarian response to endometriosis. *Reproduction* 2015;150:297–310.
  197. Koukoura O, Sifakis S, Spandidos DA. DNA methylation in endometriosis [review]. *Mol Med Rep* 2016;13:2939–48.
  198. Zidan HE, Rezk NA, Alnemr AA, Abd El Ghany AM. COX-2 gene promoter DNA methylation status in eutopic and ectopic endometrium of Egyptian women with endometriosis. *J Reprod Immunol* 2015;112:63–7.
  199. Meyer R. Zur frage der Urnieren-genese van Adenomyomen. *Zentralbl Gynakol* 1923;15:577–87.
  200. Russell WW. Aberrant portions of the müllerian duct found in an ovary. *Johns Hopkins Hosp Bull* 1899;94–96:8–10.
  201. Sampson JA. Heterotopic or misplaced endometrial tissue. *Am J Obstet Gynecol* 1925;10:649–64.

202. Cron RS, Gey G. The viability of cast-off menstrual endometrium. *Am J Obstet Gynecol* 1927;13:645–7.
203. Ridley JH, Edwards IK. Experimental endometriosis in the human. *Am J Obstet Gynecol* 1958;76:783–90.
204. Nap AW, Groothuis PG, Demir AY, Maas JW, Dunselman GA, de Goeij AF, et al. Tissue integrity is essential for ectopic implantation of human endometrium in the chicken chorioallantoic membrane. *Hum Reprod* 2003;18:30–4.
205. Arcellana RC, Robinson TW, Tyson RW, Joyce MR. McKusick-Kaufman syndrome with legal complications of hydrometrocolpos and congenital endometriosis. *J Perinatol* 1996;16:220–3.
206. Kissler S, Marx K, Scholtes M, Pfeiffer S, Meier W, Neulen J. Predisposition of subtle endometriotic lesions predominantly on the left side assessed by transvaginal hydrolaparoscopy (THL). *Eur J Obstet Gynecol Reprod Biol* 2011;158:285–8.
207. Al-Fozan H, Tulandi T. Left lateral predisposition of endometriosis and endometrioma. *Obstet Gynecol* 2003;101:164–6.
208. Puttemans P, Benagiano G, Gargett C, Romero R, Guo SW, Brosens I. Neonatal uterine bleeding as a biomarker for reproductive disorders during adolescence: a worldwide call for systematic registration by nurse midwife. *J Matern Fetal Neonatal Med* 2017;30:1434–6.
209. Brosens I, Benagiano G. The endometrium from the neonate to the adolescent. *J Matern Fetal Neonatal Med* 2016;29:1195–9.
210. Brosens I, Benagiano G, Brosens JJ. The potential perinatal origin of placental disorders in the young primigravida. *Am J Obstet Gynecol* 2015;212:580–5.
211. Brosens I, Benagiano G. Perinatal origin of endometriosis revisited. *Gynecol Endocrinol* 2015;31:419–21.
212. Bianchi P, Benagiano G, Brosens I. Promoting awareness of neonatal menstruation. *Gynecol Endocrinol* 2017;33:173–8.
213. Brosens I, Gargett CE, Guo SW, Puttemans P, Gordts S, Brosens JJ, et al. Origins and progression of adolescent endometriosis. *Reprod Sci* 2016;23:1282–8.
214. Brosens I, Curcic A, Vejnovic T, Gargett CE, Brosens JJ, Benagiano G. The perinatal origins of major reproductive disorders in the adolescent: research avenues. *Placenta* 2015;36:341–4.
215. Gargett CE, Schwab KE, Brosens JJ, Puttemans P, Benagiano G, Brosens I. Potential role of endometrial stem/progenitor cells in the pathogenesis of early-onset endometriosis. *Mol Hum Reprod* 2014;20:591–8.
216. Brosens I, Brosens J, Benagiano G. Neonatal uterine bleeding as antecedent of pelvic endometriosis. *Hum Reprod* 2013;28:2893–7.
217. Brosens I, Benagiano G. Is neonatal uterine bleeding involved in the pathogenesis of endometriosis as a source of stem cells? *Fertil Steril* 2013;100:622–3.
218. Brosens I, Puttemans P, Benagiano G. Endometriosis: a life cycle approach? *Am J Obstet Gynecol* 2013;209:307–16.
219. Marsh EE, Laufer MR. Endometriosis in premenarcheal girls who do not have an associated obstructive anomaly. *Fertil Steril* 2005;83:758–60.
220. Davis AC, Goldberg JM. Extrapelvic endometriosis. *Semin Reprod Med* 2017;35:98–101.
221. Sasson IE, Taylor HS. Stem cells and the pathogenesis of endometriosis. *Ann N Y Acad Sci* 2008;1127:106–15.
222. Oliveira FR, Dela CC, Del Puerto HL, Vilamil QT, Reis FM, Camargos AF. Stem cells: are they the answer to the puzzling etiology of endometriosis? *Histol Histopathol* 2012;27:23–9.
223. Mirantes C, Espinosa I, Ferrer I, Dolcet X, Prat J, Matias-Guiu X. Epithelial-to-mesenchymal transition and stem cells in endometrial cancer. *Hum Pathol* 2013;44:1973–81.
224. Gurung S, Deane JA, Masuda H, Maruyama T, Gargett CE. Stem cells in endometrial physiology. *Semin Reprod Med* 2015;33:326–32.
225. Hufnagel D, Li F, Cosar E, Krikun G, Taylor HS. The role of stem cells in the etiology and pathophysiology of endometriosis. *Semin Reprod Med* 2015;33:333–40.
226. Ulukus M. Stem cells in endometrium and endometriosis. *Womens Health (Lond)* 2015;11:587–95.
227. Xu Y, Zhu H, Zhao D, Tan J. Endometrial stem cells: clinical application and pathological roles. *Int J Clin Exp Med* 2015;8:22039–44.
228. Koippallil Gopalakrishnan AR, Kishore U, Madan T. Mesenchymal stem cells: a promising tool for targeted gene therapy of endometriosis. *Regen Med* 2017;12:69–76.
229. Pittatore G, Moggio A, Benedetto C, Bussolati B, Revelli A. Endometrial adult/progenitor stem cells: pathogenetic theory and new antiangiogenic approach for endometriosis therapy. *Reprod Sci* 2014;21:296–304.
230. Maruyama T, Yoshimura Y. Stem cell theory for the pathogenesis of endometriosis. *Front Biosci (Elite Ed)* 2012;4:2854–63.
231. Du H, Taylor HS. Stem cells and reproduction. *Curr Opin Obstet Gynecol* 2010;22:235–41.
232. Savilova AM, Farkhat KN, Yushina MN, Rudimova YV, Makiyan ZN, Adamyan LV. Characteristics of multipotent mesenchymal stromal cells isolated from the endometrium and endometriosis lesions of women with malformations of the internal reproductive organs. *Bull Exp Biol Med* 2017;162:539–44.
233. Gargett CE, Masuda H. Adult stem cells in the endometrium. *Mol Hum Reprod* 2010;16:818–34.
234. Du H, Taylor HS. Contribution of bone marrow-derived stem cells to endometrium and endometriosis. *Stem Cells* 2007;25:2082–6.
235. Fernandez Shaw S, Clarke MT, Hicks B, Naish CE, Barlow DH, Starkey PM. Bone marrow-derived cell populations in uterine and ectopic endometrium. *Hum Reprod* 1995;10:2285–9.
236. Zhang WB, Cheng MJ, Huang YT, Jiang W, Cong Q, Zheng YF, et al. A study in vitro on differentiation of bone marrow mesenchymal stem cells into endometrial epithelial cells in mice. *Eur J Obstet Gynecol Reprod Biol* 2012;160:185–90.
237. Sakr S, Naqvi H, Komm B, Taylor HS. Endometriosis impairs bone marrow-derived stem cell recruitment to the uterus whereas bazedoxifene treatment leads to endometriosis regression and improved uterine stem cell engraftment. *Endocrinology* 2014;155:1489–97.
238. Moridi I, Mamillapalli R, Cosar E, Ersoy GS, Taylor HS. Bone marrow stem cell chemotactic activity is induced by elevated CXCL12 in endometriosis. *Reprod Sci* 2017;24:526–33.
239. Ibrahim MG, Chiantera V, Frangini S, Younes S, Kohler C, Taube ET, et al. Ultramicro-trauma in the endometrial-myometrial junctional zone and pale cell migration in adenomyosis. *Fertil Steril* 2015;104:1475–83.
240. Tapmeier TT, Becker CM. Is pale the way to go to understand adenomyosis? *Fertil Steril* 2015;104:1378.
241. Makiyan Z. Endometriosis origin from primordial germ cells. *Organogenesis* 2017;13:95–102.
242. Signorile PG, Baldi A. Endometriosis: new concepts in the pathogenesis. *Int J Biochem Cell Biol* 2010;42:778–80.
243. Donnez J, van Langendonck A, Casanas-Roux F, van Gossum JP, Pirard C, Jadoul P, et al. Current thinking on the pathogenesis of endometriosis. *Gynecol Obstet Invest* 2002;54(Suppl 1):52–8.
244. Zhang Q, Duan J, Liu X, Guo SW. Platelets drive smooth muscle metaplasia and fibrogenesis in endometriosis through epithelial-mesenchymal transition and fibroblast-to-myofibroblast transdifferentiation. *Mol Cell Endocrinol* 2016;428:1–16.
245. Lucas PA. Stem cells for mesothelial repair: an understudied modality. *Int J Artif Organs* 2007;30:550–6.
246. Koninckx PR, Barlow D, Kennedy S. Implantation versus infiltration: the Sampson versus the endometriotic disease theory. *Gynecol Obstet Invest* 1999;47(Suppl 1):3–9.
247. Koninckx PR. Is mild endometriosis a condition occurring intermittently in all women? *Hum Reprod* 1994;9:2202–5.
248. Donnez J, Binda MM, Donnez O, Dolmans MM. Oxidative stress in the pelvic cavity and its role in the pathogenesis of endometriosis. *Fertil Steril* 2016;106:1011–7.
249. Krakauer DC, Plotkin JB. Redundancy, antiredundancy, and the robustness of genomes. *Proc Natl Acad Sci U S A* 2002;99:1405–9.
250. Harlev A, Gupta S, Agarwal A. Targeting oxidative stress to treat endometriosis. *Expert Opin Ther Targets* 2015:1–18.
251. Donnez O, van Langendonck A, Defrere S, Colette S, van Kerk O, Dehoux JP, et al. Induction of endometriotic nodules in an experimental baboon model mimicking human deep nodular lesions. *Fertil Steril* 2013;99:783–9.



252. Rier SE, Martin DC, Bowman RE, Dmowski WP, Becker JL. Endometriosis in rhesus monkeys (*Macaca mulatta*) following chronic exposure to 2,3,7,8-tetrachlorodibenzo-*p*-dioxin. *Fundam Appl Toxicol* 1993;21:433–41.
253. Orellana R, Garcia-Solares J, Donnez J, van Kerk O, Dolmans MM, Donnez O. Important role of collective cell migration and nerve fiber density in the development of deep nodular endometriosis. *Fertil Steril* 2017; 107:987–95.e5.
254. Donnez O, Soares M, Defrere S, Dehoux JP, van Langendonck A, Donnez J, et al. Nerve fiber density in deep nodular endometriotic lesions induced in a baboon experimental model. *Fertil Steril* 2013;100:1144–50.
255. Knudson AG Jr. Mutation and cancer: statistical study of retinoblastoma. *Proc Natl Acad U S A* 1971;68:820–3.
256. Nirgianakis K, Gasparri ML, Radan AP, Villiger A, McKinnon B, Mueller MD. Obstetrical complications after laparoscopic excision of posterior deep infiltrating endometriosis: a case-control study. *Fertil Steril* 2018;110:459–66.
257. Geyer FC, Weigelt B, Natrajan R, Lambros MB, de Biase D, Vatcheva R, et al. Molecular analysis reveals a genetic basis for the phenotypic diversity of metaplastic breast carcinomas. *J Pathol* 2010;220:562–73.
258. Dagogo-Jack I, Shaw AT. Tumour heterogeneity and resistance to cancer therapies. *Nat Rev Clin Oncol* 2018;15:81–94.
259. McGranahan N, Swanton C. Clonal heterogeneity and tumor evolution: past, present, and the future. *Cell* 2017;168:613–28.
260. Anaf V, Simon P, Fayt I, Noel J. Smooth muscles are frequent components of endometriotic lesions. *Hum Reprod* 2000;15:767–71.
261. Bolton AE, Pockley AG, Clough KJ, Mowles EA, Stoker RJ, Westwood OM, et al. Identification of placental protein 14 as an immunosuppressive factor in human reproduction. *Lancet* 1987;1:593–5.
262. Okamoto N, Uchida A, Takakura K, Kariya Y, Kanzaki H, Riittinen L, et al. Suppression by human placental protein 14 of natural killer cell activity. *Am J Reprod Immunol* 1991;26:137–42.
263. Gordts S, Koninckx P, Brosens I. Pathogenesis of deep endometriosis. *Fertil Steril* 2017;108:872–85.
264. Guo SW. Fibrogenesis resulting from cyclic bleeding: the Holy Grail of the natural history of ectopic endometrium. *Hum Reprod* 2018;33:353–6.
265. Leyendecker G, Wildt L, Mall G. The pathophysiology of endometriosis and adenomyosis: tissue injury and repair. *Arch Gynecol Obstet* 2009;280: 529–38.
266. Leyendecker G, Bilgicyildirim A, Inacker M, Stalf T, Huppert P, Mall G, et al. Adenomyosis and endometriosis. Re-visiting their association and further insights into the mechanisms of auto-traumatisation. An MRI study. *Arch Gynecol Obstet* 2015;291:917–32.
267. Hackett JA, Zyllicz JJ, Surani MA. Parallel mechanisms of epigenetic reprogramming in the germline. *Trends Genet* 2012;28:164–74.
268. Deans C, Maggert KA. What do you mean, “epigenetic”? *Genetics* 2015; 199:887–96.
269. National Institutes of Health. Roadmap Epigenomics Project. Available at: <http://www.roadmapepigenomics.org/overview/>. Accessed February 5, 2018.
270. Nagy C, Turecki G. Transgenerational epigenetic inheritance: an open discussion. *Epigenomics* 2015;7:781–90.
271. Tosh D, Horb ME. Chapter 11—how cells change their phenotype. In: Lanza R, Atala A, editors. *Handbook of stem cells*. 2nd ed. San Diego: Academic Press; 2013:95–100.
272. Berger SL, Kouzarides T, Shiekhattar R, Shilatifard A. An operational definition of epigenetics. *Genes Dev* 2009;23:781–3.
273. Laganà AS, Vitale SG, Salmeri FM, Triolo O, Frangez HB, Vrtacnik-Bokal E, et al. Unus pro omnibus, omnes pro uno: a novel, evidence-based, unifying theory for the pathogenesis of endometriosis. *Med Hypotheses* 2017;103: 10–20.
274. Adamyan LV, Spitsyn VA, Andreeva EN. *Comprehensive monograph on etiology and pathogenesis of endometriosis from the standpoint of genetics*. Moscow: Geotar Media; 2008.
275. Somigliana E, Infantino M, Candiani M, Vignali M, Chiodini A, Busacca M, et al. Association rate between deep peritoneal endometriosis and other forms of the disease: pathogenetic implications. *Hum Reprod* 2004;19: 168–71.

**Patogénesis de la endometriosis: La teoría de la genética/epigenética**

**Objetivo:** Estudiar la fisiopatología de la endometriosis.

**Diseño:** Resumen de las observaciones sobre endometriosis.

**Entorno:** No aplicable.

**Paciente(s):** Ninguno.

**Intervenciones:** Ninguna.

**Principal(es) medida(s) de resultado(s):** La hipótesis es compatible con todas las observaciones.

**Resultado(s):** La endometriosis, tejido similar al endometrio fuera del útero, tiene una apariencia macroscópica variable y una historia natural poco comprendida. Es una enfermedad hereditaria y heterogénea con muchos cambios bioquímicos en las lesiones, que son de origen clonal. Se asocia con dolor, infertilidad, adenomiosis y cambios en la zona de unión, placentación, inmunología, plasma, líquido peritoneal e inflamación crónica de la cavidad peritoneal. La hipótesis de Sampson de la implantación de células endometriales como consecuencia de menstruación retrógrada, la diseminación angiogénica, la diseminación linfogénica o la teoría de la metaplasia no pueden explicar todas las observaciones si la metaplasia es definida como células con cambios reversibles y un comportamiento/morfología anormales debido a un ambiente anormal. Proponemos un mecanismo poligenético/ poliepigenético. El conjunto de incidentes genéticos y epigenéticos transmitidos al nacer podría explicar los aspectos hereditarios, la predisposición, y los cambios asociados a la endometriosis en el endometrio, en la inmunología y en la placentación. Para desarrollar los típicos quistes ováricos o las lesiones de endometriosis profunda, es necesario que ocurra una serie variable de incidentes genéticos y epigenéticos transmisibles en una célula que puede variar desde células endometriales hasta células madre. Las lesiones sutiles se visualizan como endometrio en un entorno diferente hasta que aparecen alteraciones adicionales. Los típicos quistes ováricos o las lesiones de endometriosis profunda son heterogéneos y representan tres enfermedades diferentes.

**Conclusión(es):** La teoría genética epigenética es compatible con todas las observaciones sobre la endometriosis. Se discuten las implicaciones para el tratamiento y la prevención.